壁報論文比賽作品 診所組
第一名

第六型成骨蛋白及熱感式幾丁質奈米膠對於誘導式幹細胞應用於牙周組織再生能力的影響

The Effect of BMP-6, Thermosensitive Chitosan Nanogel and iPS Cell Application on Periodontal Tissue Regeneration

葉光大[1]，黃國光[2]
Kuang-Dah Yeh, DDS, MDS, PhD[1], Kuo-Kuang Huang, DDS, MDS[2]
梵谷美學牙醫

PURPOSE

此實驗目的是希望可了解牙髓細胞來源的iPS細胞是否較其它iPS細胞更具再生成牙周組織的潛力，同時也欲了解若添加BMP-6可否更加有效誘導iPS細胞朝牙周組織（ex. 牙周韌帶、牙骨質、齒槽骨）方向分化。

MATERIALS & METHODS

2006年，Takahashi & Yamanaka利用基因轉殖技術將Oct3/4、Sox2、c-Myc、Klf4 transfect入老鼠胚胎纖維母細胞內，發展出iPS誘導性多潛力幹細胞株(induced pluripotent stem cells)，其iPS細胞擁有與胚胎幹細胞相似的形態與生長特性，表現出胚胎幹細胞特有的標誌基因，亦如胚胎幹細胞般，可分化產生出含有內胚層、中胚層以及外胚層三種胚層細胞分子標記的細胞，但卻可避免使用胚胎幹細胞的道德爭議與免疫排斥問題。骨骼缺損是臨床上一個常見的問題，嚴重的牙周疾病將會導致齒槽骨的缺損，影響到病人的咀嚼能力和顏面美觀。現今齒槽骨缺損的治療方法主要是自體骨移植或是以PRP混合骨粉並加上人工膜，但是這些方法皆有其優缺點，例如自體骨移植雖無免疫排斥反應，但並不是所有人皆有足夠的骨質來源，且因其製造傷口，還是會有術後感染的疑慮，而骨粉的來源幾乎全是由豬或牛而來也有安全上的風險。又牙周組織再生現行最有效的治療方法為添加EMD(豬的牙釉質萃取物)於缺損區誘導牙周組織再生，然其成功率及再生量仍無法預期。EMD的成分中，現今最為人廣泛使用的生長因子為BMP-2，然BMP-2雖可促進齒槽骨再生，但無法成功長成牙周韌帶以及牙堊質，且可能會產生齒槽骨沾黏的現象，是我們並不樂見的結果。在文獻(Huang et al. 2006)中指出，BMP-6可以成功使牙周組織再生而不會有沾黏的現象，故我們使用BMP-6為生長因子與iPS細胞一起培養用以再生牙周相關組織。考慮及但若直接將細胞覆於傷口上，則細胞可能流失，因此若添

加一載體，不但可有效承載細胞讓其達到修復再生的能力，也可緩慢釋放BMP-6等有效成分，在(Cheng et al. 2011)文章中即指出，以chitosan為基底之熱感式奈米膠可以有效的提供細胞3D立體生長環境且對細胞亦無毒性。，此膠在4度C時為流動態，在37度C時即凝為膠狀，所以可有效貼覆著我們欲修復的牙周傷口部位，提供內存細胞修復損傷的機會。另外在其他的實驗方法中，加入骨分化培養液，需經過21天才可達到誘導出骨細胞分化出的效果，常趕不上上皮長入的速度，故我們希望加入BMP-6可使骨細胞分化加速，一方面修補長回完全的牙周組織如牙周韌帶及牙堊質等，一方面也修補回所有原先高度寬度的齒槽骨。

STUDY DESIGN

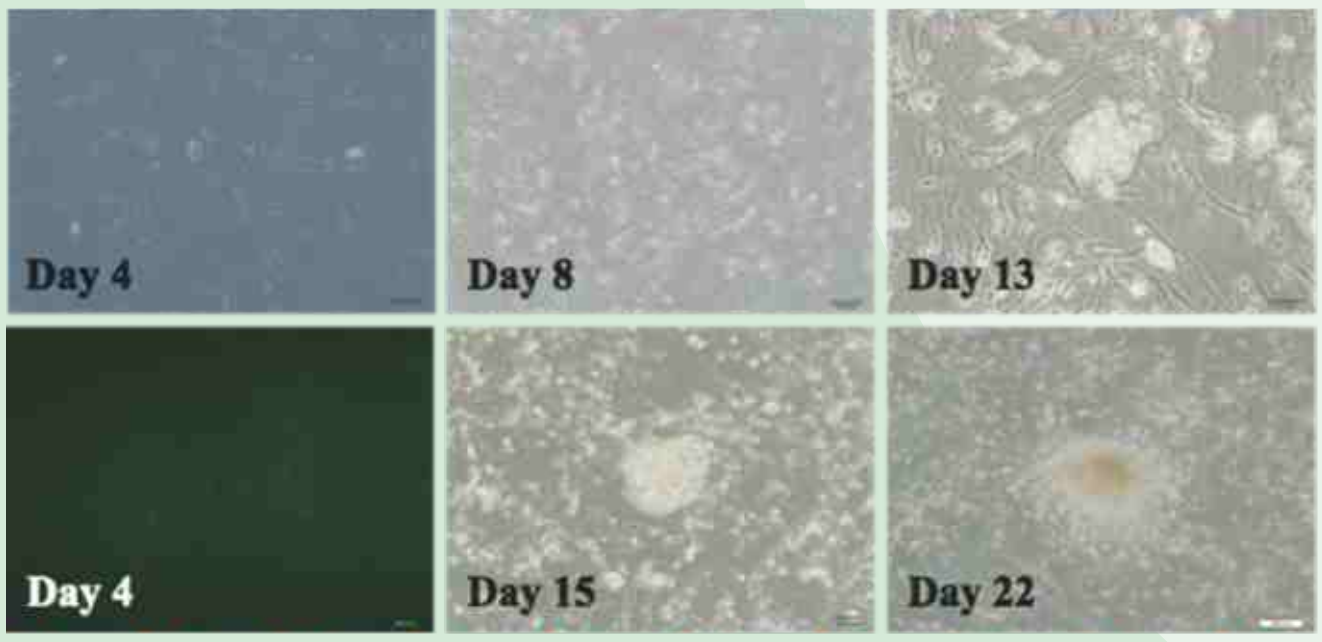

圖一、牙髓細胞reprogram成iPS細胞的過程。

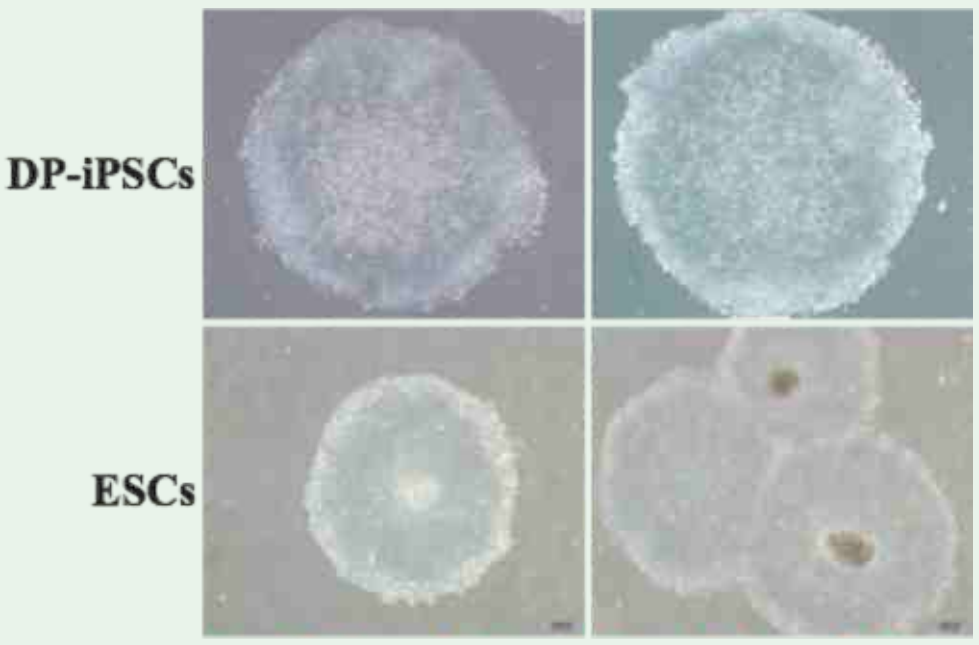

圖二、牙髓細胞形成Embryoid body。

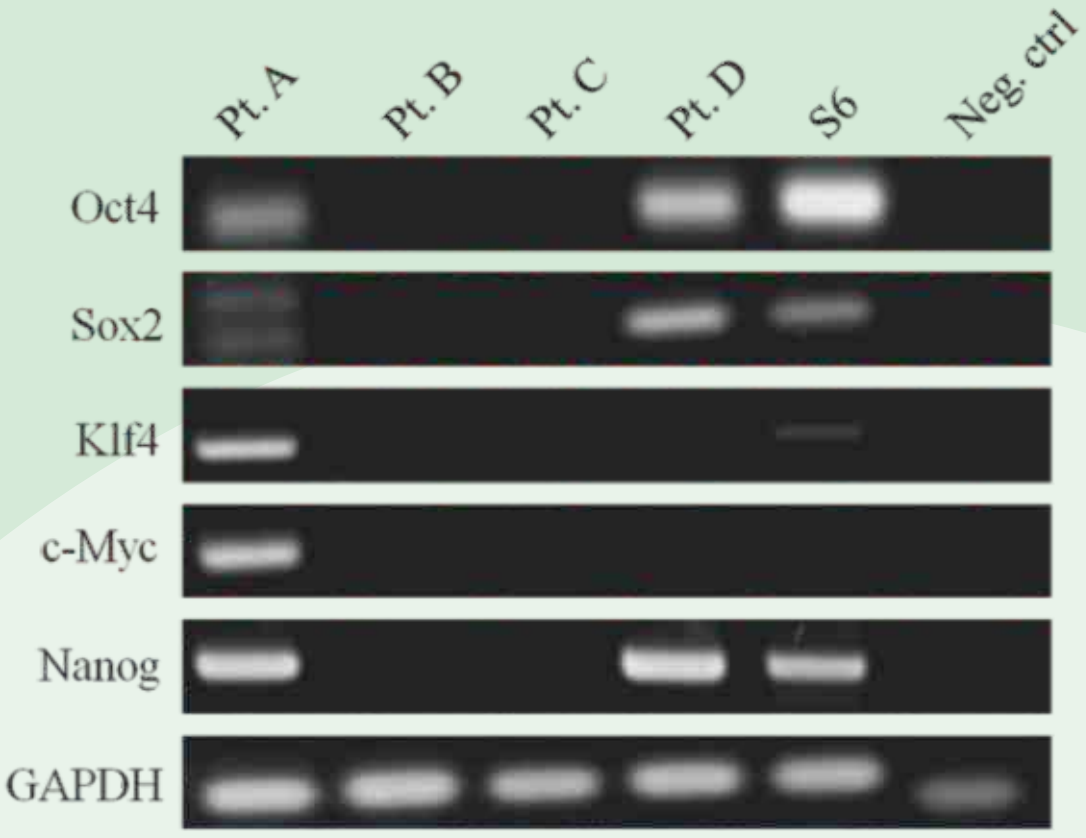

圖三、牙髓細胞iPS表現出胚胎幹細胞基因。

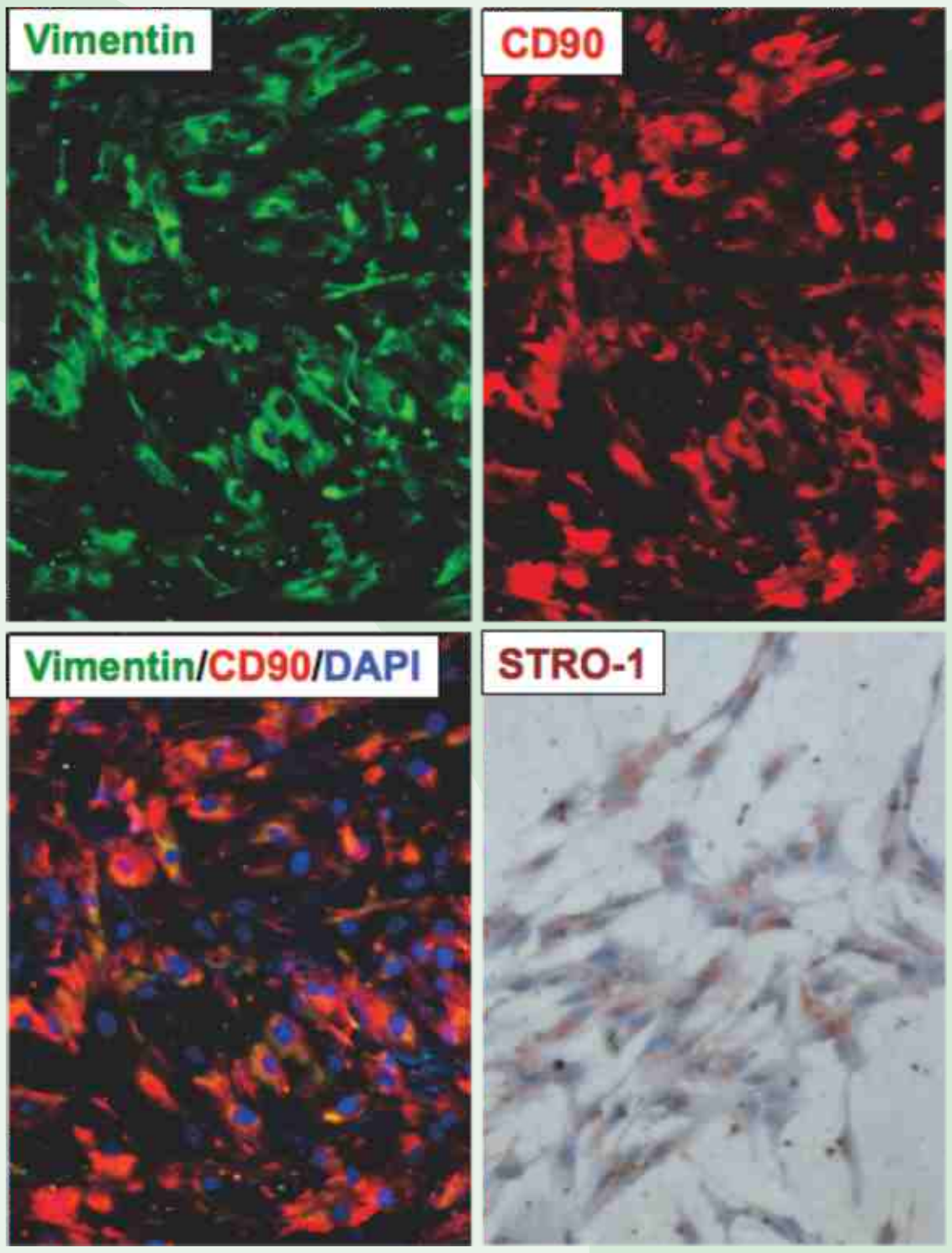

圖四、免疫螢光染色亦證實牙髓細胞iPS表現出胚胎幹細胞基因。

RESULTS

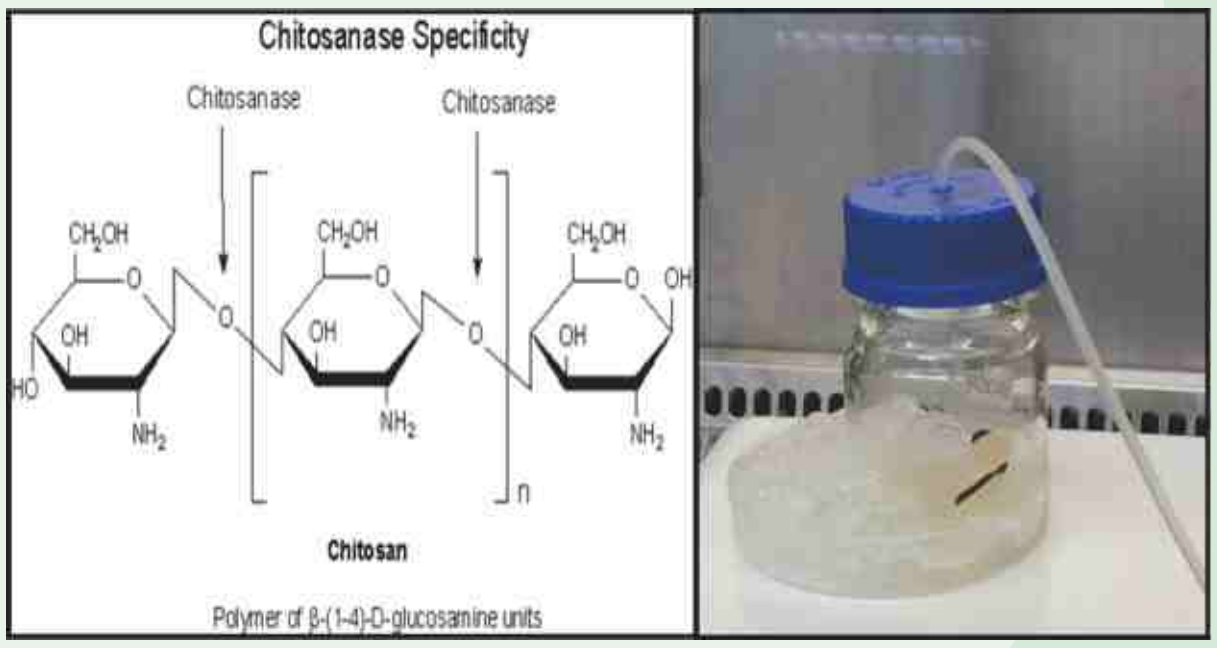

圖五、熱感式奈米膠的製作過程。將Chitosan加入0.1M acetic acid內，放入stir bar後，隔天離心取上清液，再加入gelatin 0.5%拿去滅菌，用飽和的β-gp緩慢滴定，並且不斷的補冰塊以保持膠體在4度C的狀況下， 滴定至pH value為7.4， 此為我們所要的膠體。



Before at 4 °C　　After at 37 °C

圖六、製成好的熱感性奈米膠，在4 °C~37°C之間為流動態，而在37 °C時可在一分鐘內成膠狀，方便我們敷在欲修復的組織傷口部位。

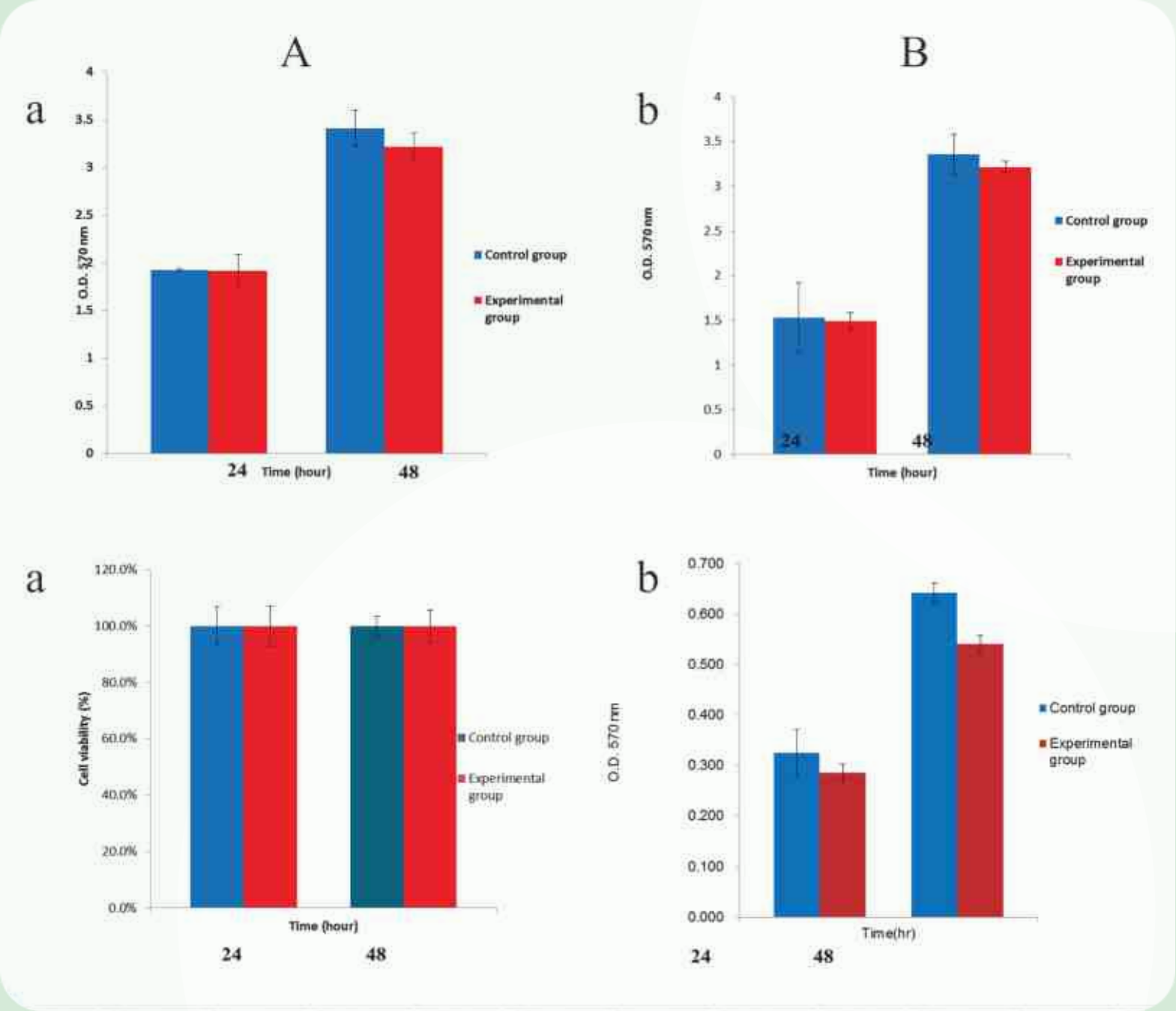

圖七、細胞毒性之測試

A.使用結晶紫染色測試膠對iPS細胞的毒性。

(a)膠的萃取液萃取出後才加入胎牛血清加入細胞培養液。

(b)先加入胎牛血清再將膠萃取液萃取出後加入細胞培養液內，在24 hr、48 hr兩個時間點比較，控制組與實驗組相比並無統計上的差異。

B.使用乳酸脫氫酶測試細胞在膠中的存活情形。

(a) iPS細胞在膠中的存活率，在24 hr、48 hr兩個時間點比較，控制組與實驗組在細胞存活率上並無統計上的差異。

(b)使用MTT測試法，iPS在膠中的存活率，在24 hr、48 hr兩個時間點比較，控制組與實驗組在細胞存活率上並無統計上的差異。

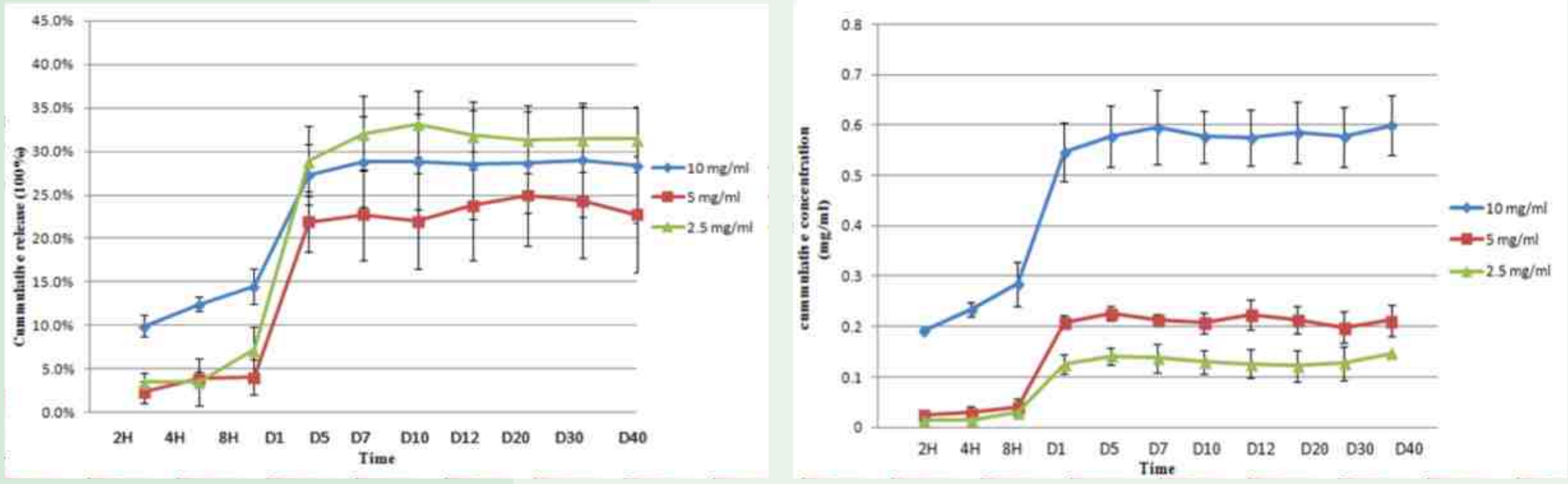

A B

圖八、

A. 為Dex在一個月中連續釋放累積的比例。 B. Dex在一個月中連續釋放累積的濃度。

可以看出三種不同濃度下，Dex緩慢的從膠體釋放後漸趨平穩，可見熱感式奈米膠具有可使承載於中的生物因子緩慢釋放的優點，因此可當作良好的生物載體。

(a) (b) (c)

圖九、

(a)添加了0.1ng/ml的BMP-6在骨分化培養液中，培養21天後以茜紅素S染色的結果。

(b)添加了1ng/ml的BMP-6在骨分化培養液中，培養21天後以茜紅素S染色的結果。

(c)單純以骨分化培養液培養21天後，以茜紅素S染色的結果。

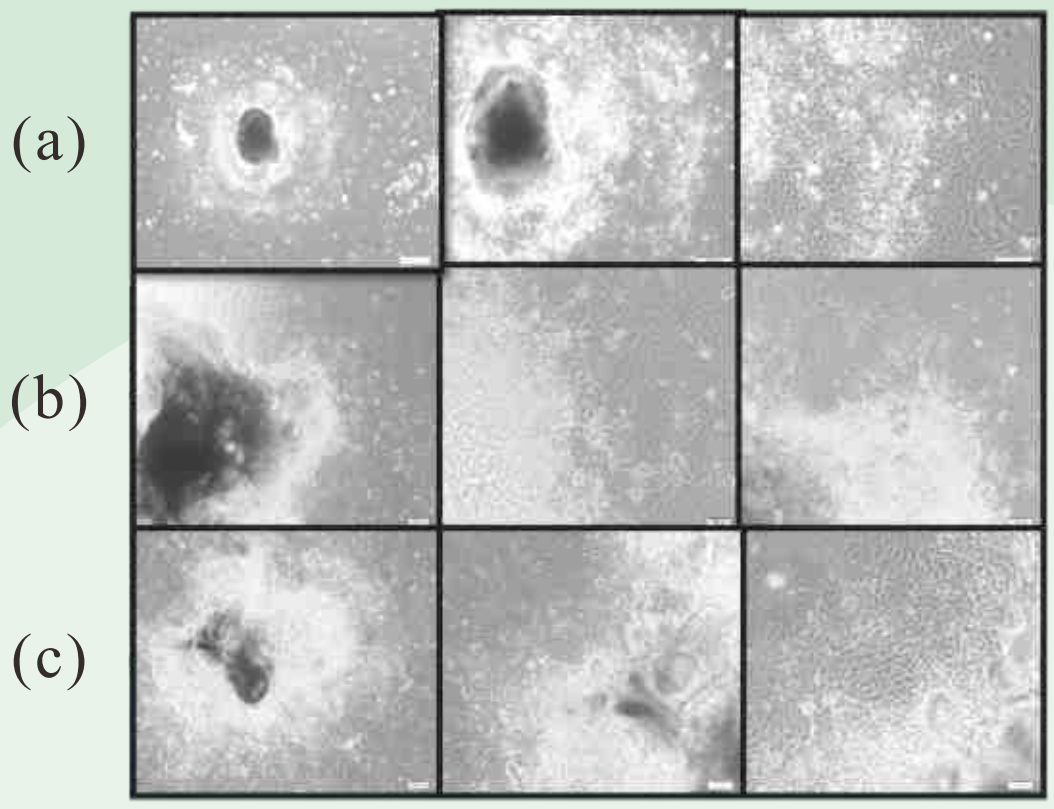

圖十、加入0.1ng/ml的BMP-6在骨分化培養液

(a)分化第七天時，在4倍視野下、20倍視野下、40倍視野下。

(b)分化第十四天時，在4倍視野下、20倍視野下、40倍視野下。

(c)分化第二十一天時，在4倍視野下、20倍視野下、40倍視野下。

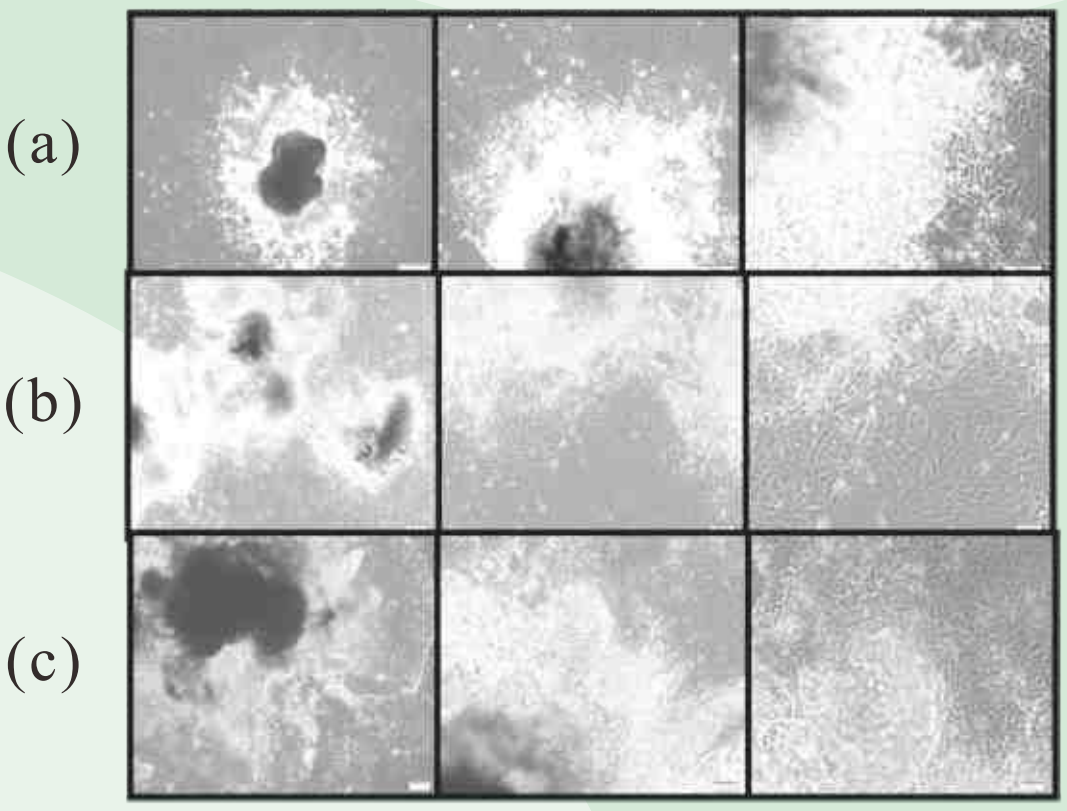

圖十一、加入1ng/ml的BMP-6在骨分化培養液

(a)分化第七天時，由左而右為在4倍視野下、20倍視野下、40倍視野下。

(b)分化第十四天時，在4倍視野下、20倍視野下、40倍視野下。

(c)分化第二十一天時，在4倍視野下、20倍視野下、40倍視野下。

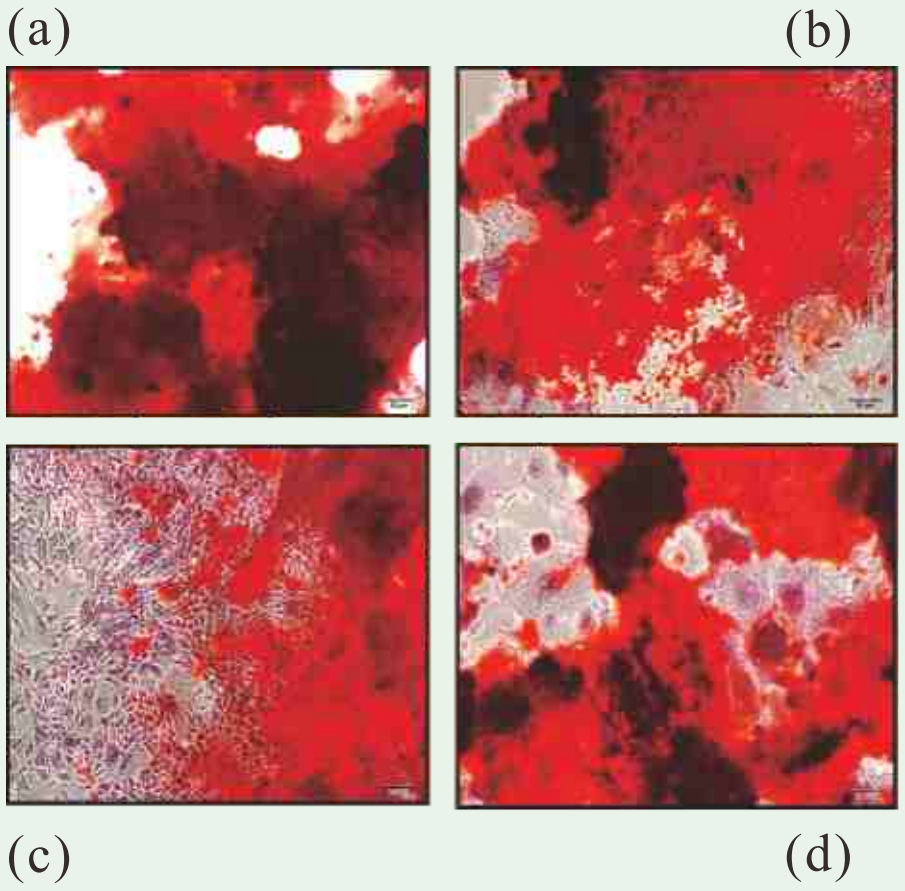

圖十二、在第21天以茜紅素染色法標誌骨細胞礦化的情形。
(a)四倍視野。
(b)十倍視野。
(c)二十倍視野。
(d)四十倍視野。

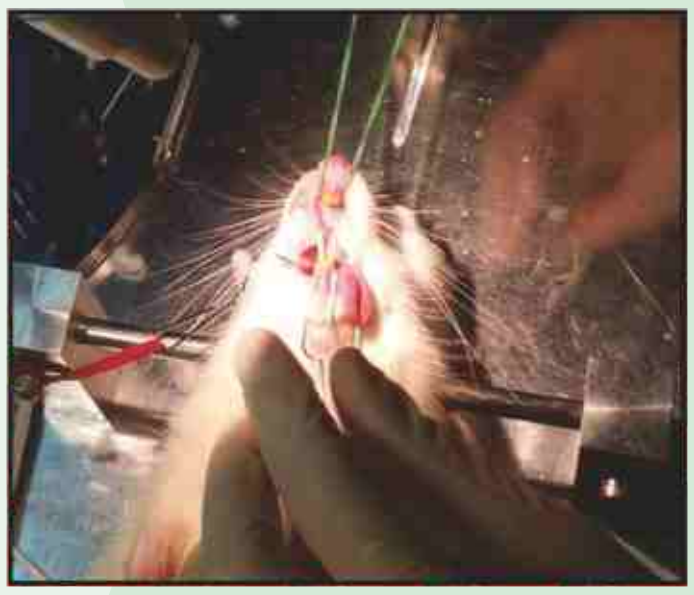

圖十三、選用12週齡的SD大鼠，以建立牙周病大鼠模式。

將SD大鼠上下顎扳開，在上顎臼齒處製造牙周傷口(包括將牙骨質磨平，以及牙周韌帶磨除)。

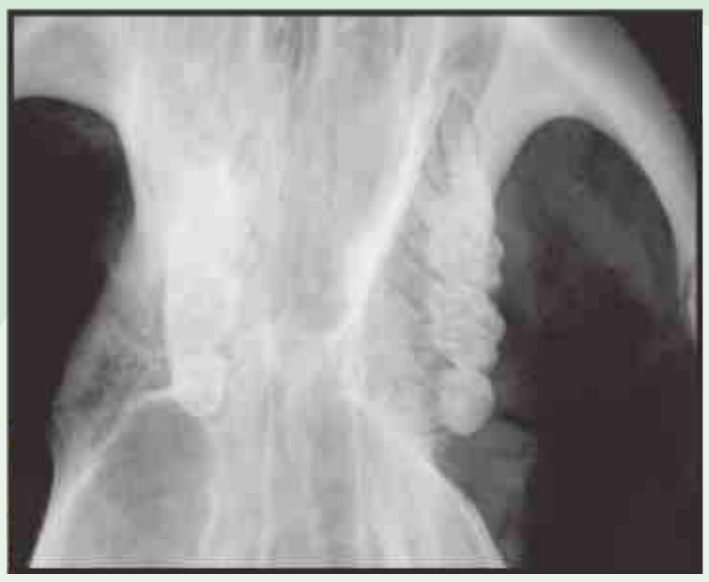

*以Micro-CT拍攝大鼠上顎臼齒處的X光影像。

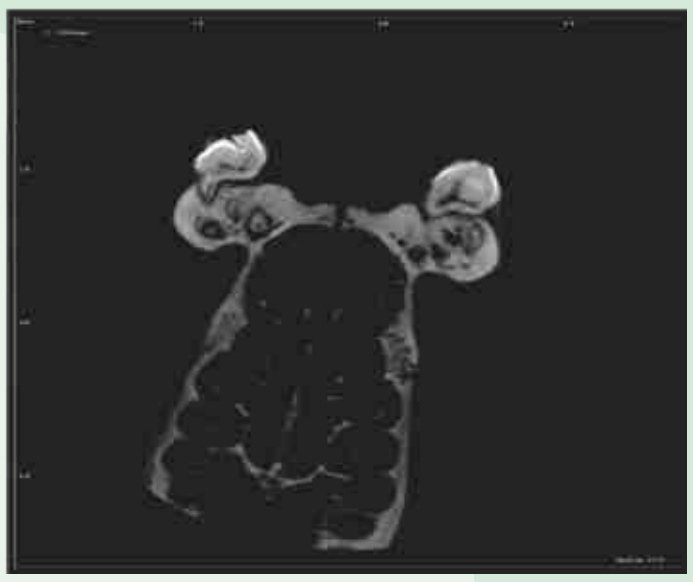

*以Micro-CT的3D analysis分析大鼠上顎處的模型。

CONCLUSION

BMP-6具有可以促進牙堊質以及牙骨質再生的能力，亦有增加骨質生成的能力。以chitosan為基底的膠具有良好的分解性，可被人體中的lysosome分解，故膠並無殘留人體的疑慮。本實驗中我們成功的誘導人類牙髓細胞成iPS誘導式幹細胞，並將細胞培養於幾丁質奈米膠中。此幾丁質奈米膠可由原本的流動性在室溫下凝成膠狀，並可緩慢持續釋出包含於其中的生物分子，且已證實對iPS細胞並無毒性，為一合適iPS細胞生長於牙周缺損的環境。本實驗加入BMP-6後，確實發現可促使骨分化速度加快，增加礦物化生成量。接下來的進度為利用已建立的大鼠動物模式（將大鼠的右側臼齒牙根處磨平以及將牙堊質磨損，藉以建立牙周損傷模式），實驗是否同時加入牙髓細胞iPS細胞及BMP-6於幾丁質奈米膠中置入牙周缺損後，可成功誘導再生出新的牙堊質、牙骨質並增加加速新的齒槽骨生成。方法包括偵測牙周組織相關的蛋白表現量，如BMP-3, OPN，來得知細胞是否有朝牙周相關組織分化。動物組織則取下以Micro-CT觀察骨質的生成量是否有明顯上升，並以H & E組織染色觀察有無牙周韌帶、牙堊質的生成。最終目的是希望可以重建完整且具有功能的牙周組織。

REFERENCES

1. Kazutoshi Takahashi and Shinya Yamanaka. Induction of Pluripotent Stem Cells from Mouse Embryonic and Adult Fibroblast Cultures by Defined Factors. Cell (2006)126, 663-676.
2. Kuo-Kuang Huang et al. Effects of bone morphogenetic protein-6 on periodontal wound healing in a fenestration defect of rats. J Periodont Res (2005), 40(1):1-10.
3. Yung-Hsin Cheng et al. Thermosensitive chitosan-gelatin-glycerol phosphate hydrogel as a controlled system of ferulic acid for nucleus pulposus regeneration. Biomaterials (2011)32:6953-61.

論文原稿

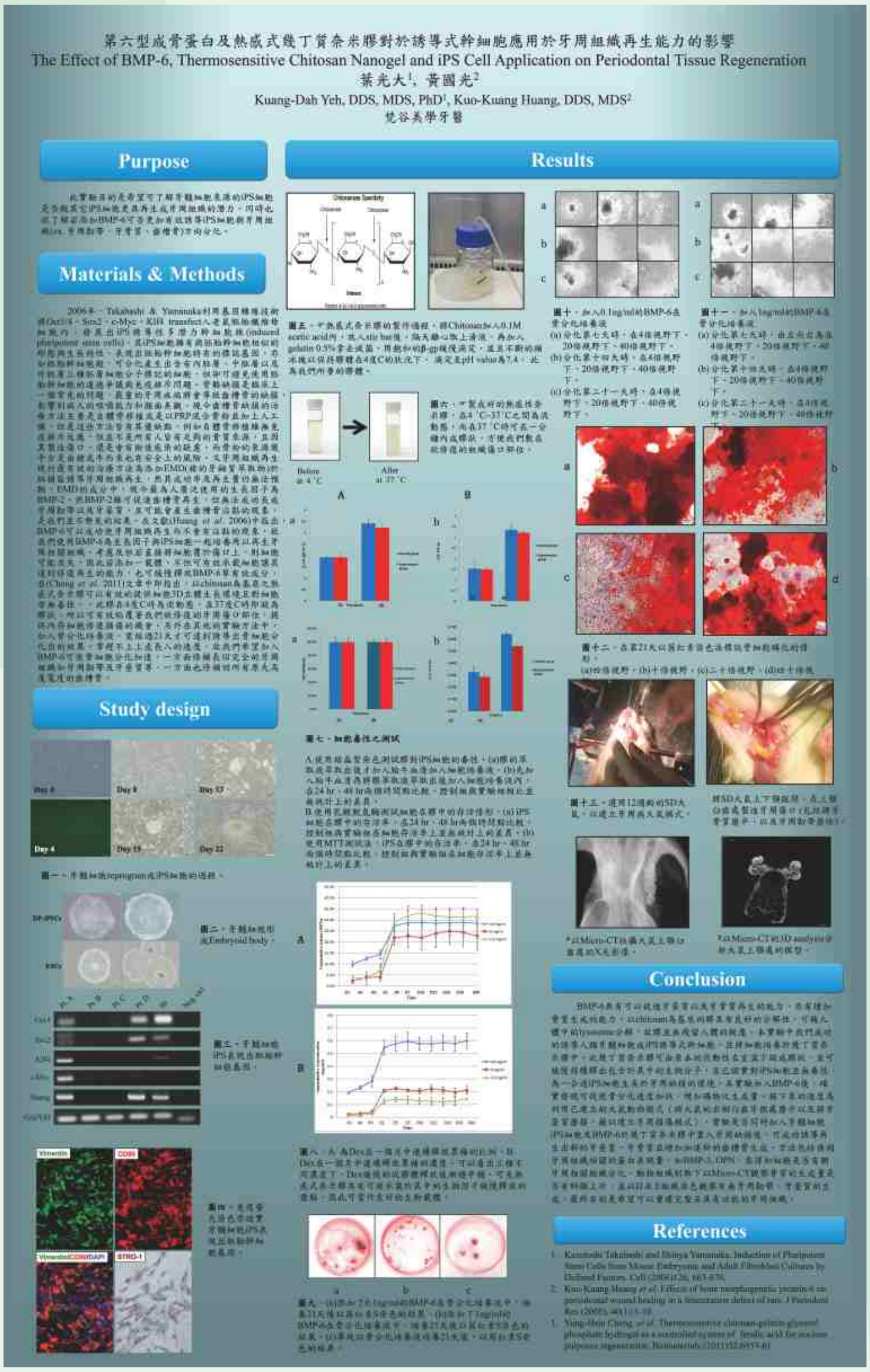

第六型成骨蛋白及熱感式幾丁質奈米膠對於誘導式幹細胞應用於牙周組織再生能力的影響

The Effect of BMP-6, Thermosensitive Chitosan Nanogel and iPS Cell Application on Periodontal Tissue Regeneration

葉光大[1], 黃國光[2]

Kuang-Dah Yeh, DDS, MDS, PhD[1], Kuo-Kuang Huang, DDS, MDS[2]

梵谷美學牙醫

Purpose

Results

Materials & Methods

Study design

Conclusion

References

壁報論文比賽作品 診所組 第二名

Herbst 裝置治療第二類異常咬合之病例報告

Treatment of Class II Malocclusion with the Herbst appliance：Case Report

廖謹正
品安牙醫診所

摘要

Herbst功能性矯正裝置的設計，是利用固定在上顎第一大臼齒及下顎第一小臼齒的金屬桿及金屬管間的套疊伸縮作用，將下顎維持在一個前伸的位置，希望能誘導下顎骨的生長，來改善第二類異常咬合關係。本次病例報告有兩位第二類異常咬合的患者，利用Herbst裝置搭配固定式矯正裝置來達到良好的治療效果。

前言

功能性矯正裝置是一種固定式或是活動式的裝置，用來改變下顎的位置，因而造成肌肉及軟組織伸展產生的力量以及牙齒與骨骼周邊神經肌的改變，藉此移動牙齒並進行生長改變。功能性矯正裝置可以分成三種形式:第一類牙齒支持活動式；第二類組織支持活動式及第三類牙齒支持固定式。Herbst 裝置原本是由Emil Herbst 在1905於德國發展出來，1934 發表關於Herbst 裝置治療的文章，之後就很少有相關的文章發表。1979 Hans Phenarzs2 再次提出Herbst 裝置的文章及臨床治療，試圖以Herbst 裝置來解決病人合作與控制生長方向的問題。自此Herbst 裝置便開始廣泛地被使用。

Herbst 裝置利用固定在上顎第一大臼齒及下顎第一小臼齒的金屬桿及金屬管間的套疊伸縮，來將下顎維持在一個前伸的位置。1996 Miller 提出 Flip-Lock Herbst，降低裝置中可活動部份的數目,可以降低斷裂或失敗,更舒適且便利於臨床使用,希望可以改善以往缺點增加治療效果。Flip-Lock Herbst 裝置的製作，臨床上需要將上顎第一大臼齒分離三天及裝置第一小臼齒的金屬環套後取模型，將模型裝上咬合器後，製作第一大臼齒不鏽鋼牙冠(或是金屬環套)，再完成Herbst裝置之焊接，最後將此Herbst 裝置取下打亮後，於門診中試戴並黏著。本病例報告便是使用Flip-Lock Herbst來進行矯正治療。

病例報告

病例一 12歲6月男孩，主述為上顎前牙暴牙。

診斷：1.外觀：臉型不對稱，凸臉型
2.前後方向：第二類咬合，水平咬覆8mm
3.垂直方向：垂直咬覆5mm
4.左右方向：空間不足
5.顳顎關節：正常

經與家長討論後，家長希望以不拔牙的方式進行矯正治療。經家長同意後採用固定式矯正裝置合併Herbst裝置進行治療。

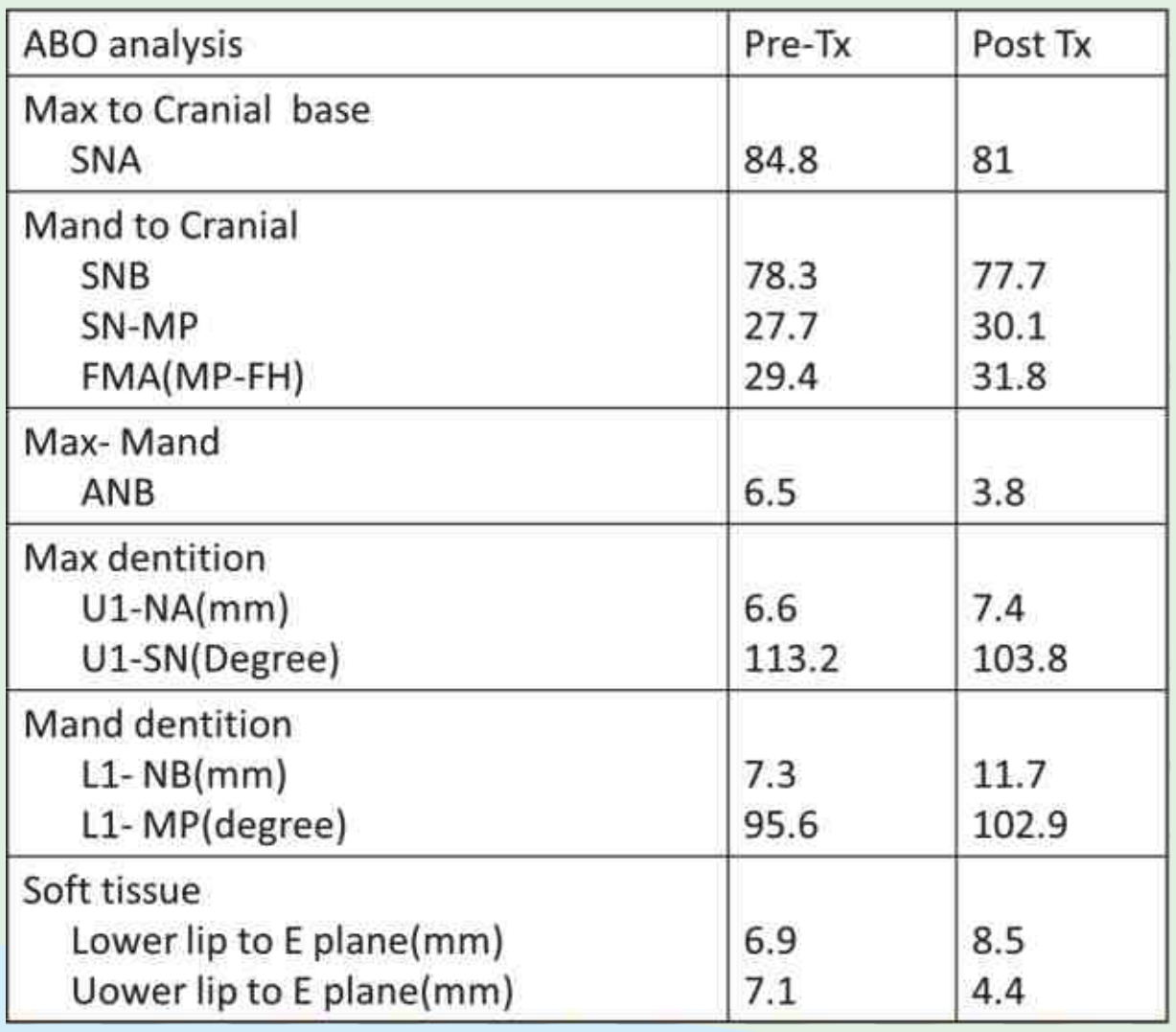

ABO analysis	Pre-Tx	Post Tx
Max to Cranial base		
SNA	84.8	81
Mand to Cranial		
SNB	78.3	77.7
SN-MP	27.7	30.1
FMA(MP-FH)	29.4	31.8
Max- Mand		
ANB	6.5	3.8
Max dentition		
U1-NA(mm)	6.6	7.4
U1-SN(Degree)	113.2	103.8
Mand dentition		
L1- NB(mm)	7.3	11.7
L1- MP(degree)	95.6	102.9
Soft tissue		
Lower lip to E plane(mm)	6.9	8.5
Uower lip to E plane(mm)	7.1	4.4

Pre-treatment
OJ: 8mm
OB: 5mm
Space deficiency:
max: -3.5mm
mand: -5.5mm

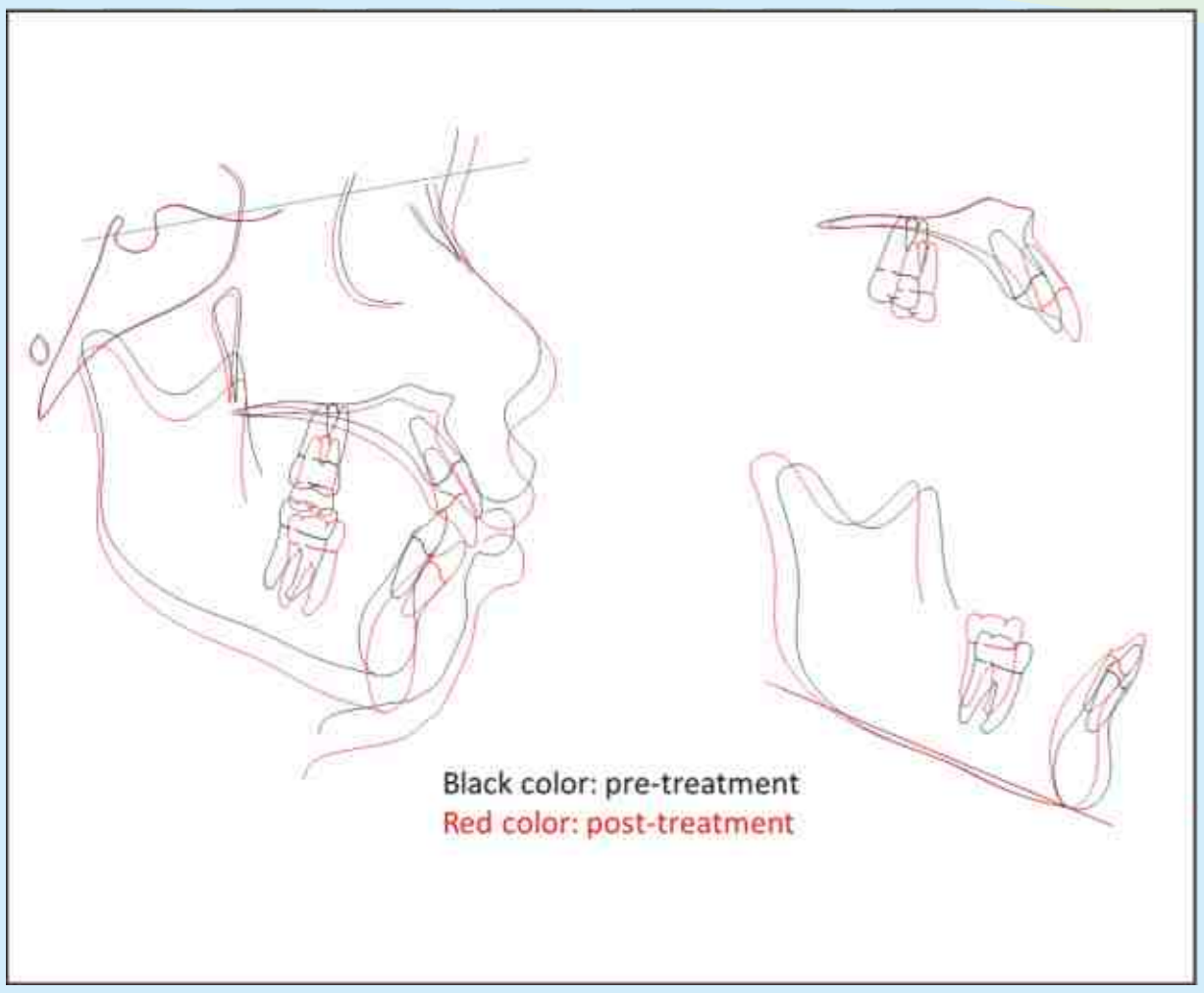

Black color: pre-treatment
Red color: post-treatment

Post-treatment
Tx time: 22 mons

病例二 10歲男孩，主述為牙齒不整齊、暴暴的。

診斷：1.外觀：臉型不對稱，正中型
2.前後方向：第二類咬合，水平咬覆9.5mm
3.垂直方向：垂直咬覆4mm
4.左右方向：空間不足，中線不對齊
5.顳顎關節：正常

經與家長討論後，家長希望以不拔牙的方式進行矯正治療。經家長同意後採用固定式矯正裝置合併Herbst裝置進行治療。

ABO analysis	Pre-Tx	Post Tx
Max to Cranial base		
SNA	78.4	80.8
Mand to Cranial		
SNB	74	77.9
SN-MP	24.7	17.7
FMA(MP-FH)	24.9	16.8
Max- Mand		
ANB	4.4	2.9
Max dentition		
U1-NA(mm)	9.4	6.7
U1-SN(Degree)	120.9	112.5
Mand dentition		
L1- NB(mm)	5.2	8.5
L1- MP(degree)	99.9	106.9
Soft tissue		
Lower lip to E plane(mm)	-0.2	1.7
Uower lip to E plane(mm)	2.9	1.8


[redacted]
[redacted]
[redacted]

Pre-treatment
OJ: 9.5mm
OB: 4mm
Space deficiency:
max: -0.7mm
mand: -5.5mm

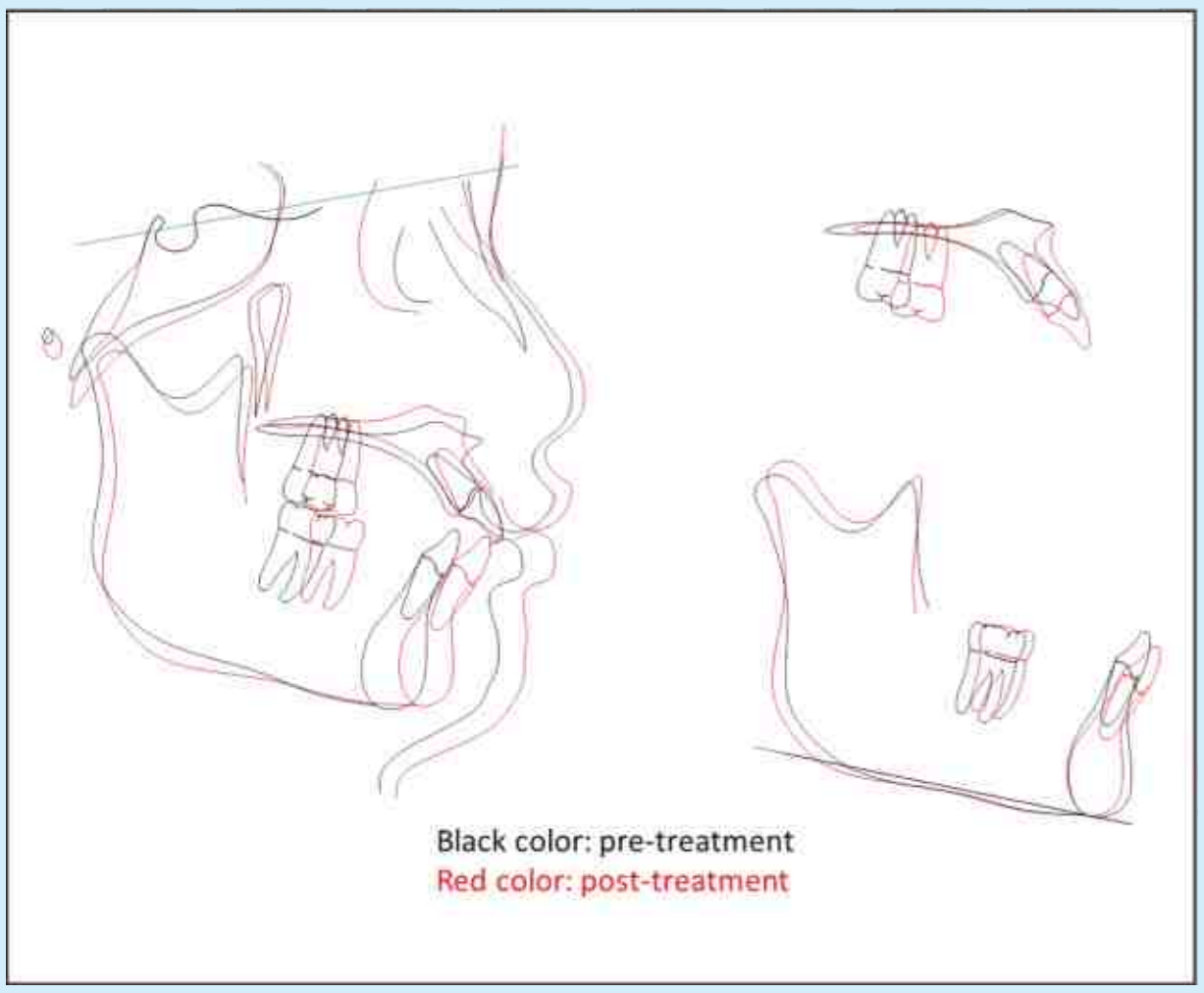

Black color: pre-treatment
Red color: post-treatment

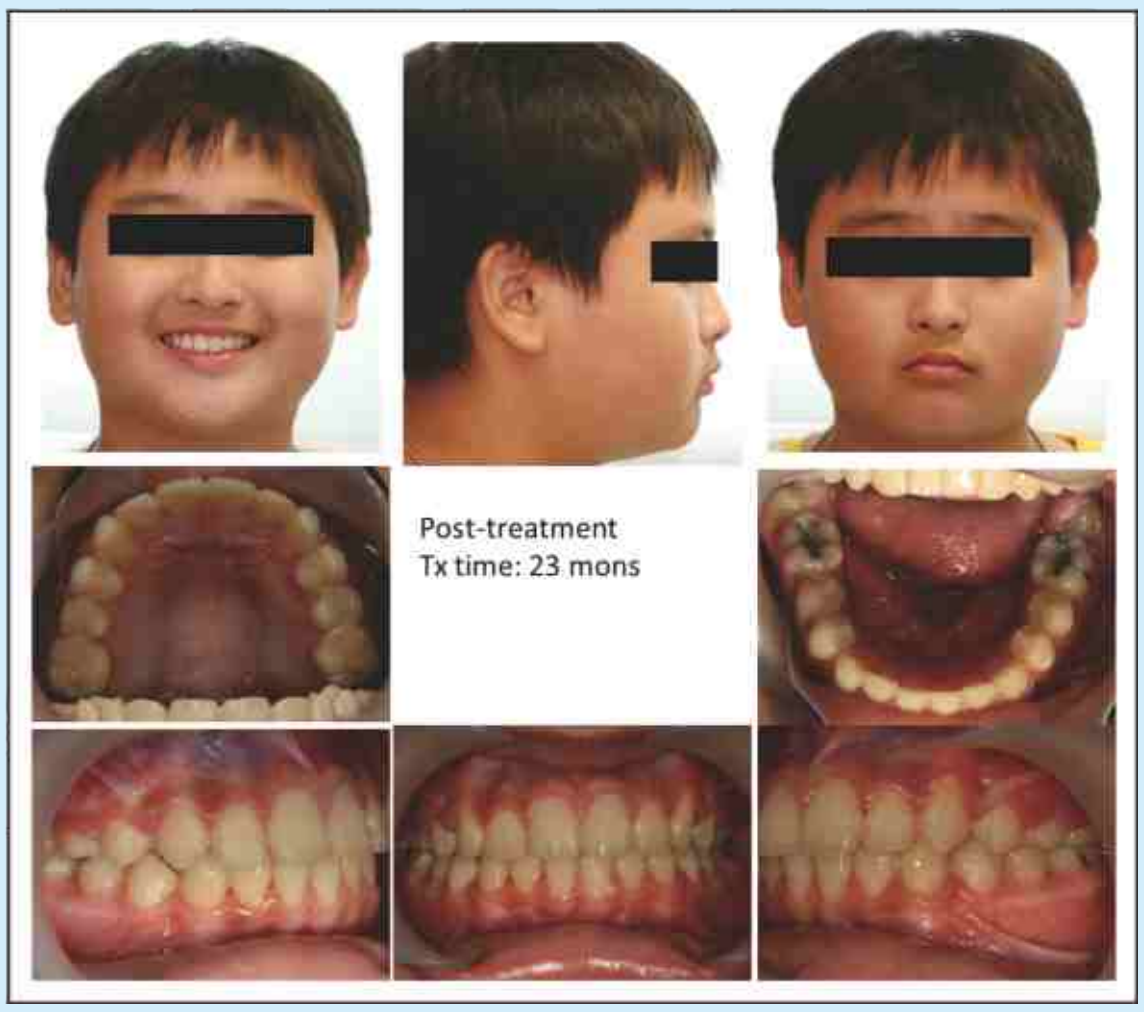
[redacted]
[redacted]
[redacted]

Post-treatment
Tx time: 23 mons

討論

有學者提出Herbst治療是唯一有效的功能性矯正裝置，可以改變下顎的生長達到臨床上顯著的效果。功能性矯正裝置的支持者提出在動物實驗

中，上下顎骨會因為將其位置前置而刺激下顎的生長。因此，部份學者認為在人類的身上應該也有相似的的效果，可以用來幫助治療第二類骨性異常咬合關係。研究顯示傳統的Herbst 裝置有能力來抑制上顎骨前後徑的生長，並增加下顎骨長度及下顏面的高度。而且只有Herbst 裝置有能力來改變下顎的生長，達到第二類異常咬合臨床上顯著的改善。有學者提出，Herbst治療可以達到有效的下顎髁突(condylar growth)生長，包括髁突的重塑、節盂窩(glenoid fossa)的重塑、髁突位置在關節盂窩內位置的改變以及下顎自轉。

顳顎關節對於功能性矯正裝置的反應機轉仍然充滿爭議。部分在動物生長期進行下顎前凸的實驗中證明關節盂窩及髁突可以發生重塑，但是有些實驗則無此發現。在過去的十年，部分學者利用電腦斷層掃描及核磁共振攝影來詳細紀錄使用Herbst 裝置對顳顎關節及齒顏面部完整的影響，他們發現在關節窩及髁突會有新骨的生成 並在放射線學檢查上形成雙重輪廓，但仍缺乏確定性的答案。可是，由靈長類動物實驗結果顯示，Herbst裝置的效果，包括：上顎及上顎牙齒向後移動、增加髁突的水平方向生長、以及下顎及下顎牙齒的向前移動。至於關節盂窩的生長方向，則由向下、後方向變為向下、前方向，而且這些部位骨頭的增生與控制組皆有達顯著差異。同時，外翼肌也不會因為功能性矯正裝置的影響而造成過度活性。

早期使用功能性矯正方式來進行治療，可以獲的較好的治療結果，可以降低日後手術的機會、避免因手術所帶來的缺點。而活動式功能性矯正裝置已歷經許多年的修改，如MARA、Twin-block等，都有學者提出類似Herbst裝置的治療結果，但仍然有部分的病人因為不合作而無法達到預期的改變。而Herbst 裝置是唯一屬於第三類牙齒支持固定式的裝置。

結論

Herbst 裝置與其他功能性矯正裝置相比，最大的優點為1.不須患者合作；2.有效控制下顎 的生長。雖然仍有需多待確定的答案，但是，由本次的案例可知，對於第二類異常咬合的患者而言，它仍是相當有效的治療方式。

Herbst 裝置治療第二類異常咬合之病例報告

Treatment of Class II Malocclusion with the Herbst appliance：Case Report

廖謹正
品安牙醫診所

摘要：

Herbst功能性矯正裝置的設計，是利用固定在上顎第一大臼齒及下顎第一小臼齒的金屬桿及金屬管間的套疊伸縮作用，將下顎維持在一個前伸的位置，希望能誘導下顎骨的生長，來改善第二類異常咬合關係。本次病例報告有兩位第二類異常咬合的患者，利用Herbst裝置搭配固定式矯正裝置來達到良好的治療效果。

前言：

功能性矯正裝置是一種固定式或是活動式的裝置，用來改變下顎的位置，因而造成肌肉及軟組織伸展產生的力量以及牙齒與骨骼周邊神經肌的改變，藉此移動牙齒並進行生長改變。功能性矯正裝置可以分成三種形式: 第一類牙齒支持活動式；第二類組織支持活動式及第三類牙齒支持固定式。Herbst 裝置原本是由Emil Herbst 在1905於德國發展出來，1934 發表關於Herbst 裝置治療的文章，之後就很少有相關的文章發表。 1979 Hans Phenarzs² 再次提出Herbst 裝置的文章及臨床治療，試圖以Herbst 裝置來解決病人合作與控制生長方向的問題。自此Herbst 裝置便開始廣泛地被使用。

Herbst 裝置利用固定在上顎第一大臼齒及下顎第一小臼齒的金屬桿及金屬管間的套疊伸縮，來將下顎維持在一個前伸的位置。1996 Miller 提出 Flip-Lock Herbst，降低裝置中可活動部份的數目, 可以降低斷裂或失敗, 更舒適且便利於臨床使用, 希望可以改善以往缺點增加治療效果。Flip-Lock Herbst 裝置的製作，臨床上需要將上顎第一大臼齒分離三天及裝置第一小臼齒的金屬環套後取模型，將模型裝上咬合器後，製作第一大臼齒不鏽鋼牙冠(或是金屬環套)，再完成Herbst裝置之焊接，最後將此Herbst 裝置取下打亮後，於門診中試戴並黏著。本病例報告便是使用Flip-Lock Herbst來進行矯正治療。

病例報告：

病例1：12歲6月男孩，主述為上顎前牙暴牙。
診斷： 1.外觀：臉型不對稱，凸臉型
2.前後方向：第二類咬合，水平咬覆8mm
3.垂直方向：垂直咬覆5mm
4.左右方向：空間不足
5.顳顎關節：正常

經與家長討論後，家長希望以不拔牙的方式進行矯正治療。經家長同意後採用固定式矯正裝置合併Herbst裝置進行治療。

ABO analysis	Pre-Tx	Post Tx
Max to Cranial base SNA	84.8	81
Mand to Cranial SNB SN-MP FMA(MP-FH)	78.3 27.7 29.4	77.7 30.1 31.8
Max- Mand ANB	6.5	3.8
Max dentition U1-NA(mm) U1-SN(Degree)	6.6 113.2	7.4 103.8
Mand dentition L1- NB(mm) L1- MP(degree)	7.3 95.6	11.7 102.9
Soft tissue Lower lip to E plane(mm) Uower lip to E plane(mm)	6.9 7.1	8.5 4.4

Black color: pre-treatment
Red color: post-treatment

Pre-treatment
OJ: 8mm
OB: 5mm
Space deficiency:
max: -3.5mm
mand: -5.5mm

Post-treatment
Tx time: 22 mons

病例2：10歲男孩，主述為牙齒不整齊，暴暴的。
診斷： 1.外觀：臉型不對稱，正中型
2.前後方向：第二類咬合，水平咬覆9.5mm
3.垂直方向：垂直咬覆4mm
4.左右方向：空間不足，中線不對齊
5.顳顎關節：正常

經與家長討論後，家長希望以不拔牙的方式進行矯正治療。經家長同意後採用固定式矯正裝置合併Herbst裝置進行治療。

ABO analysis	Pre-Tx	Post Tx
Max to Cranial base SNA	78.4	80.8
Mand to Cranial SNB SN-MP FMA(MP-FH)	74 24.7 24.9	77.9 17.7 16.8
Max- Mand ANB	4.4	2.9
Max dentition U1-NA(mm) U1-SN(Degree)	9.4 120.9	6.7 112.5
Mand dentition L1- NB(mm) L1- MP(degree)	5.2 99.9	8.5 106.9
Soft tissue Lower lip to E plane(mm) Uower lip to E plane(mm)	-0.2 2.9	1.7 1.8

Black color: pre-treatment
Red color: post-treatment

Pre-treatment
OJ: 9.5mm
OB: 4mm
Space deficiency:
max: -0.7mm
mand: -5.5mm

Post-treatment
Tx time: 23 mons

討論：

有學者提出Herbst治療是唯一有效的功能性矯正裝置，可以改變下顎的生長達到臨床上顯著的效果。功能性矯正裝置的支持者提出在動物實驗中，上下顎骨會因為將其位置前置而刺激下顎的生長。因此，部份學者認為在人類的身上應該也有相似的的效果，可以用來幫助治療第二類骨性異常咬合關係。研究顯示傳統的Herbst 裝置有能力來抑制上顎骨前後徑的生長，並增加下顎骨長度及下顏面的高度。而且只有Herbst 裝置有能力來改變下顎的生長，達到第二類異常咬合臨床上顯著的改善。有學者提出，Herbst治療可以達到有效的下顎髁突(condylar growth)生長，包括髁突的重塑，節盂窩(glenoid fossa)的重塑，髁突位置在關節盂窩內位置的改變以及下顎自轉。

顳顎關節對於功能性矯正裝置的反應機轉仍然充滿爭議。部分在動物生長期進行下顎前凸的實驗中證明關節盂窩及髁突可以發生重塑，但是有些實驗則無此發現。在過去的十年，部分學者利用電腦斷層掃描及核磁共振攝影來詳細紀錄使用Herbst 裝置對顳顎關節及齒顏面部完整的影響，他們發現在關節窩及髁突會有新骨的生成 並在放射線學檢查上形成雙重輪廓，但仍缺乏確定性的答案。可是，由靈長類動物實驗結果顯示，Herbst裝置的效果，包括：上顎及上顎牙齒向後移動，增加髁突的水平方向生長，以及下顎及下顎牙齒的向前移動。至於關節盂窩的生長方向，則由向下，後方向變為向下，前方向，而且這些部位骨頭的增生與控制組皆有達顯著差異。同時，外翼肌也不會因為功能性矯正裝置的影響而造成過度活性。

早期使用功能性矯正方式來進行治療，可以獲的較好的治療結果，可以降低日後手術的機會，避免因手術所帶來的缺點。而活動式功能性矯正裝置已歷經許多年的修改，如MARA，Twin-block等，都有學者提出類似Herbst裝置的治療結果，但仍然有部分的病人因為不合作而無法達到預期的改變。而Herbst 裝置是唯一屬於第三類牙齒支持固定式的裝置。

結論：

Herbst 裝置與其他功能性矯正裝置相比，最大的優點為1.不須患者合作；2.有效控制下顎 的生長。雖然仍有需多待確定的答案，但是，由本次的案例可知，對於第二類異常咬合的患者而言，它仍是相當有效的治療方式。

壁報論文比賽作品 診所組 第三名

Effect of manganese on variations of microstructure and mechanical properties of Fe-Cr-C-based biomedical alloy

kuo-kuang Huang[1,4]*, Mao-Hung Cheng[1,2,3,4], Y. R. Chou[1], Tzu-Pan Lee[4]

梵谷牙醫診所　黃國光醫師

Abstract

The microstructure and mechanical properties of the high strength Fe-5Cr-2Mn-0.15C biomedical alloy were investigated by means of optical microscopy, electron microscopy, hardness and tensile testing. Based on the research results, the microstructure of the alloy underwent solution heat-treatment at 1100° C for 30 min was a single lath-like martensite structure. No other precipitates could be found in the matrix of the as-quenched alloy. The lath-like martensite phase belongs to BCC structure with lattice constant 0.287 nm. The as-quenched alloy following low temperature tempering at 120°C for 8 h exhibited the maximum tensile strength (~1500 MPa), yield strength (~1440 MPa), elongation (~13.7%) and hardness (~Hv 400). After aged at temperatures ranging from 450°C to 650°C, the mechanical properties of the alloy decreased with increasing the aged temperatures and soaking times. It was found that the ferrite (α) phase was formed in the matrix of the alloy aged at 450°C, and the amounts and grain sizes of the α phase increased with increasing the aged temperatures and soaking times. Therefore, the α phase plays a crucial role in decreasing the mechanical properties of the Fe-5Cr-2Mn-0.15C biomedical alloy. It is believe that the high strength Fe-5Cr-2Mn-0.15C biomedical alloy is a potential material for implants and dental orthodontic devices applications.

Introduction

Ferrous-based alloys, including Fe-Ni-Cr and Fe-Al-Mn, are adopted extensively in such orthopedic and dental implants because of their favorable mechanical characteristics and excellent biocompatibility. A dense oxide layer is the main factor resulting in the excellent biocompatibility. The oxide layer is always present in oxidizing media as in the human body fluid, and rebuilt with in milliseconds after damaging. Moreover, our previous studies have also reported that some carbides were formed on Fe-Al-Mn and Fe-Al-Mn-C-base alloys, following phase transformation by heat-treatment and surface functionalization. These carbides have important role in forming nanostructure and oxidation layer, then increasing the alloy biocompatibility. Hence, the ferrous-based alloys could be used as alternative to some expensive metal-based biomedical alloys (such as Ti-based alloys and Co-based alloys) in clinical usage, due to its price advantage and mechanical properties. Recently, we have attempted to development a high-strength, well corrosion resistance good biocompatibility and cheaper ferrous-based biomedical alloy. It was found that the Fe-5Cr-2Mn-0.15C (Fe-520) alloy possess theses attractive properties. In the Fe-520 alloy system, Cr addition can improves the corrosion and oxidation resistance behavior. The addition of Mn increases solution strengthening and enhances mechanical properties at high temperatures. C plays an important role for promoting precipitating strength of ferrous-based alloys. It is generally concluded that the Fe-520 alloy possesses excellent properties such as high-strength, good corrosion and oxidation resistance, superior workability, and price advantage. Thus, it could be developed as a promising potential ferrous-based biomedical alloy. However, as a potential biomaterial, understanding the microstructure transition behavior and mechanical properties are great importance in the applications. Moreover, the microstructure feature has also significantly influence on the biocompatibility and corrosion resistance of the alloy. Therefore, the purpose of the present study is to investigate the microstructure and mechanical properties of the Fe-520 biomedical alloy and thus provide related information for biocompatibility and corrosion resistance tests in the future.

Materials and Methods

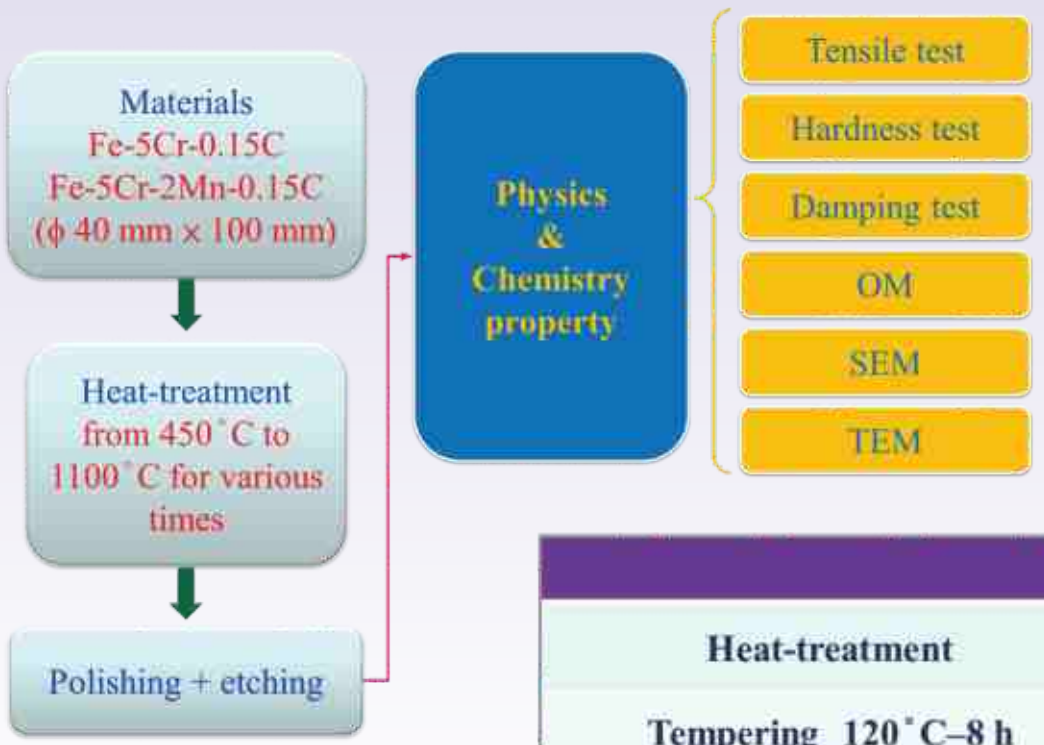

Materials
Fe-5Cr-0.15C
Fe-5Cr-2Mn-0.15C
(ϕ 40 mm × 100 mm)

Heat-treatment from 450˚C to 1100˚C for various times

Polishing + etching

Physics & Chemistry property

Tensile test
Hardness test
Damping test
OM
SEM
TEM

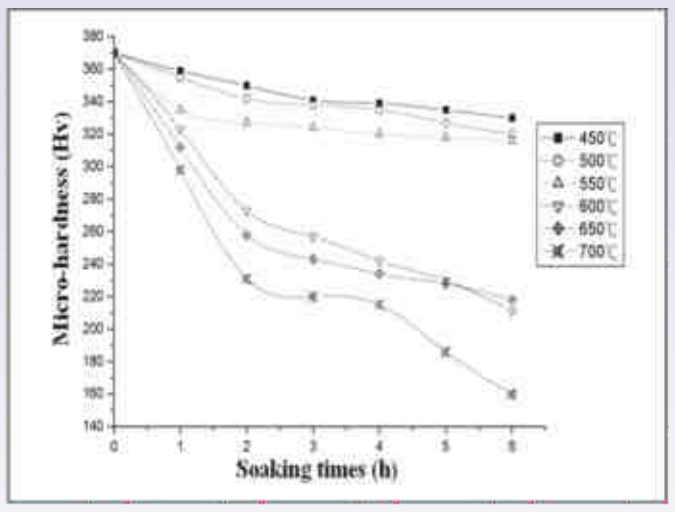

Micro-hardness of the as-quenched Fe-5Cr-0.15C alloy aged at temperatures ranging from 450°C to 700°C for various times.

Heat-treatment	Mechanical properties		
	Tensile strength (MPa)	Yield strength (MPa)	Elogation (%)
Tempering 120˚C–8 h	1500	1440	13.5
Tempering 220˚C–8 h	1460	1390	13.6
Tempering 120˚C–8 hand aging 450˚C–8 h	1450	1350	14.9
Tempering 220˚C–8 hand aging 550˚C–8 h	1000	890	21.6



(a) a zone axis [111] bright-field image taken from the matrix of the as-quenched Fe-5Cr-2Mn-0.15C alloy, (b) the α′ martensite DF and (c) a zone axis [111] SAEDP taken from the α′ martensite in (a).

Optical micrograph of the as-quenched Fe-5Cr-2Mn-0.15C alloy.



(a) a zone axis [001] bright-field image taken from the matrix of the as-quenched Fe-5Cr-2Mn-0.15C alloy aged at 650°C for 8 h, (b) the α phase DF.



(a) a zone axis [111] bright-field image taken from the matrix of the as-quenched Fe-5Cr-2Mn-0.15C alloy tempered at 120°C for 8 h and (b) the tempered martenite phase DF.

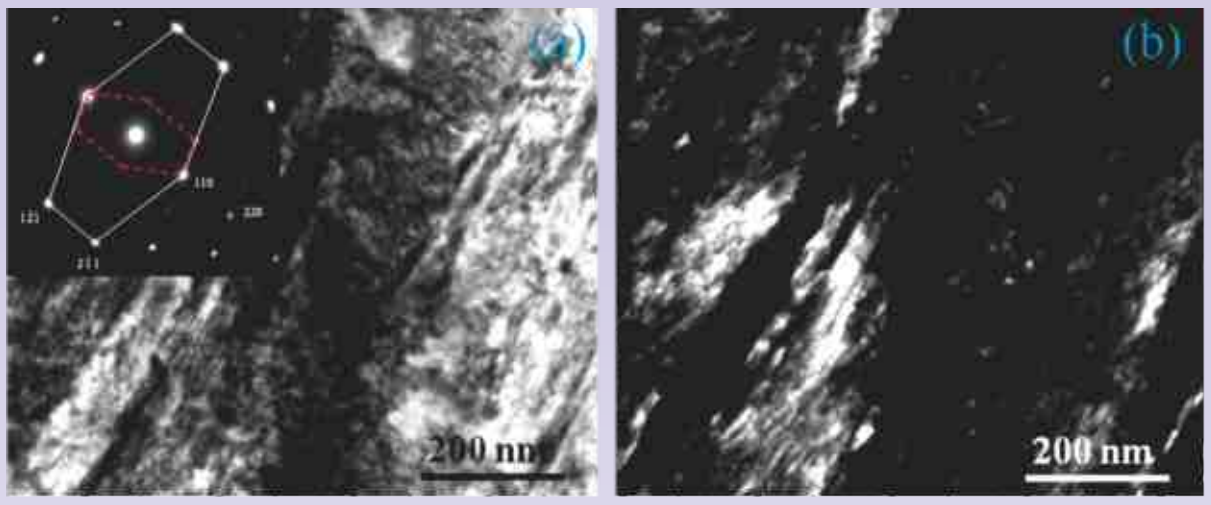

(a) a zone axis [113] bright-field image taken from the matrix of the as-quenched Fe-5Cr-2Mn-0.15C alloy tempered at 220°C for 8 h and then aged at 650°C for 8 h (b) the α phase DF.



(a) a zone axis [111] bright-field image taken from the matrix of the as-quenched Fe-5Cr-0.15C alloy tempered at 120°C for 8 h (b) the tempered martensite phase DF.

Results and Discussion

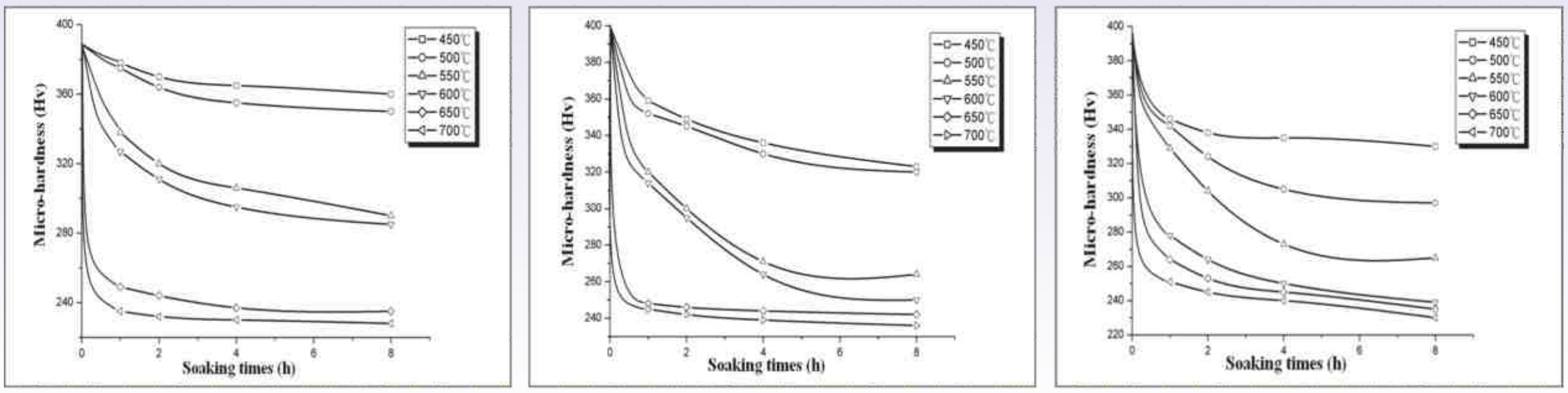

Micro-hardness of the Fe-5Cr-2Mn-0.15C alloy with various heat-treatments: (a) as-quenched, (b) as-quenched then tempered at 120°C for 8 h, and (c) as-quenched then tempered at 220°C for 8 h.

Heat-treatment	Mechanical properties		
	Tensile strength (MPa)	Yield strength (MPa)	Elogation (%)
As-quenched 1100˚C–30 min	1280	1210	13.1
aging 450˚C–1.5 h	1170	1105	16.4
aging 450˚C–2.5 h	1185	1115	16.1
aging 450˚C–13.5 h	1195	1120	15.9
aging 550˚C–1.5 h	1120	1045	15.4
aging 550˚C–2.5 h	1345	1070	17.3
aging 550˚C–13.5 h	1170	1095	19.2
aging 650˚C–1.5 h	755	730	16.2
aging 650˚C–2.5 h	705	675	18.6
aging 650˚C–13.5 h	640	610	24.2



(a) a zone axis [001] bright-field image taken from the matrix of the as-quenched Fe-5Cr-2Mn-0.15C alloy tempered at 120°C for 8 h and then aged at 650°C for 8 h (b) the α phase DF.

Conclusion

- The best processed condition of the Fe-5Cr-2Mn-0.15C alloy is low temperature tempering at 120oC for 8 h after solution treatment. The tensile strength 1450~1500 MPa, yield strength 1385~1440 MPa and elongation 13.5~13.7%.
- The as-quenched Fe-5Cr-0.15C alloy tempered at 120oC for 8 h possess the maximum mechanical properties (tensile strength 1360~1365 MPa, yield strength 1250~1300 MPa and elongation 17.5~18.3%). It was found that the Fe-5Cr-0.15C alloy without Mn, the tensile strength descend is about 90~135 Mpa.
- The microstructure of alloy is mar-tempering structure by treating at 1100oC for 30 min. Its crystal structure belongs to the BCC structure t. The lattice constant is 0.287 nm.

論文原稿

Effect of manganese on variations of microstructure and mechanical properties of Fe-Cr-C-based biomedical alloy

kuo-kuang Huang[1,4*], Mao-Hung Cheng[1,2,3,4], Y. R. Chou[1], Tzu-Pan Lee[4]

梵谷牙醫診所　黃國光醫師

Abstract

The microstructure and mechanical properties of the high strength Fe-5Cr-2Mn-0.15C biomedical alloy were investigated by means of optical microscopy, electron microscopy, hardness and tensile testing. Based on the research results, the microstructure of the alloy underwent solution heat-treatment at 1100˚C for 30 min was a single lath-like martensite structure. No other precipitates could be found in the matrix of the as-quenched alloy. The lath-like martensite phase belongs to BCC structure with lattice constant 0.287 nm. The as-quenched alloy following low temperature tempering at 120˚C for 8 h exhibited the maximum tensile strength (~1500 MPa), yield strength (~1440 MPa), elongation (~13.7%) and hardness (~Hv 400). After aged at temperatures ranging from 450˚C to 650˚C, the mechanical properties of the alloy decreased with increasing the aged temperatures and soaking times. It was found that the ferrite (α) phase was formed in the matrix of the alloy aged at 450˚C, and the amounts and grain sizes of the α phase increased with increasing the aged temperatures and soaking times. Therefore, the α phase plays a crucial role in decreasing the mechanical properties of the Fe-5Cr-2Mn-0.15C biomedical alloy. It is believe that the high strength Fe-5Cr-2Mn-0.15C biomedical alloy is a potential material for implants and dental orthodontic devices applications.

Introduction

Ferrous-based alloys, including Fe-Ni-Cr and Fe-Al-Mn, are adopted extensively in such orthopedic and dental implants because of their favorable mechanical characteristics and excellent biocompatibility. A dense oxide layer is the main factor resulting in the excellent biocompatibility. The oxide layer is always present in oxidizing media as in the human body fluid, and rebuilt with in milliseconds after damaging. Moreover, our previous studies have also reported that some carbides were formed on Fe-Al-Mn and Fe-Al-Mn-C-base alloys, following phase transformation by heat-treatment and surface functionalization. These carbides have important role in forming nanostructure and oxidation layer, then increasing the alloy biocompatibility. Hence, the ferrous-based alloys could be used as alternative to some expensive metal-based biomedical alloys (such as Ti-based alloys and Co-based alloys) in clinical usage, due to its price advantage and mechanical properties. Recently, we have attempted to development a high-strength, well corrosion resistance good biocompatibility and cheaper ferrous-based biomedical alloy. It was found that the Fe-5Cr-2Mn-0.15C (Fe-520) alloy possess theses attractive properties. In the Fe-520 alloy system, Cr addition can improves the corrosion and oxidation resistance behavior. The addition of Mn increases solution strengthening and enhances mechanical properties at high temperatures. C plays an important role for promoting precipitating strength of ferrous-based alloys. It is generally concluded that the Fe-520 alloy possesses excellent properties such as high-strength, good corrosion and oxidation resistance, superior workability, and price advantage. Thus, it could be developed as a promising potential ferrous-based biomedical alloy. However, as a potential biomaterial, understanding the microstructure transition behavior and mechanical properties are great importance in the applications. Moreover, the microstructure feature has also significantly influence on the biocompatibility and corrosion resistance of the alloy. Therefore, the purpose of the present study is to investigate the microstructure and mechanical properties of the Fe-520 biomedical alloy and thus provide related information for biocompatibility and corrosion resistance tests in the future.

Materials and Methods

Materials
Fe-5Cr-0.15C
Fe-5Cr-2Mn-0.15C
(ϕ 40 mm × 100 mm)

Heat-treatment
from 450˚C to
1100˚C for various
times

Polishing + etching

Physics
&
Chemistry
property

- Tensile test
- Hardness test
- Damping test
- OM
- SEM
- TEM

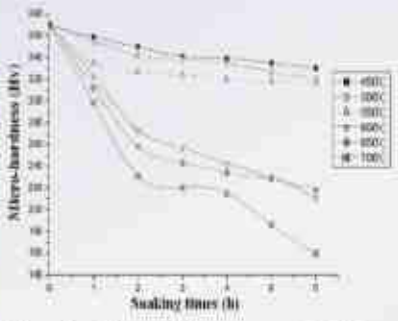

Micro-hardness of the as-quenched Fe-5Cr-0.15C alloy aged at temperatures ranging from 450˚C to 700˚C for various times.

Heat-treatment	Mechanical properties Tensile strength (MPa)	Yield strength (MPa)	Elogation (%)
Tempering 120˚C–8 h	1500	1440	13.5
Tempering 220˚C–8 h	1460	1390	13.6
Tempering 120˚C–8 hand aging 450˚C–8 h	1450	1350	14.9
Tempering 220˚C–8 hand aging 550˚C–8 h	1000	890	21.6



(a) a zone axis $[\bar{1}11]$ bright-field image taken from the matrix of the as-quenched Fe-5Cr-2Mn-0.15C alloy, (b) the α' martensite DF and (c) a zone axis $[\bar{1}11]$ SAEDP taken from the α' martensite in (a).

Optical micrograph of the as-quenched Fe-5Cr-2Mn-0.15C alloy.

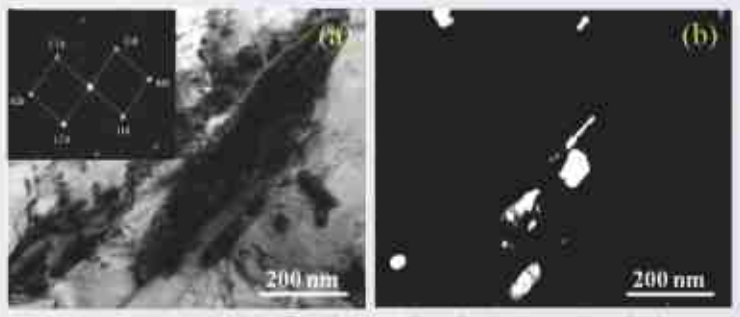

(a) a zone axis [001] bright-field image taken from the matrix of the as-quenched Fe-5Cr-2Mn-0.15C alloy aged at 650˚C for 8 h, (b) the α phase DF.

(a) a zone axis $[\bar{1}11]$ bright-field image taken from the matrix of the as-quenched Fe-5Cr-2Mn-0.15C alloy tempered at 120˚C for 8 h and (b) the tempered martenite phase DF.

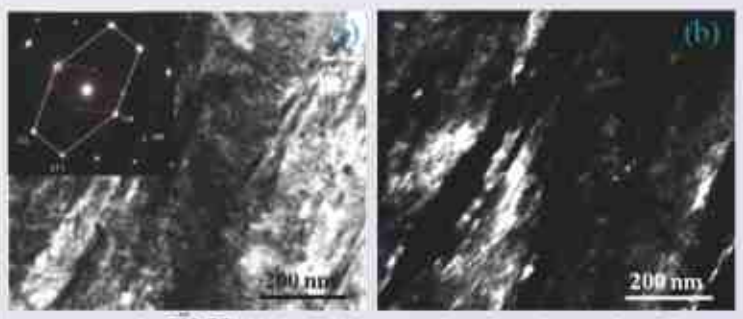

(a) a zone axis $[\bar{1}13]$ bright-field image taken from the matrix of the as-quenched Fe-5Cr-2Mn-0.15C alloy tempered at 220˚C for 8 h and then aged at 650˚C for 8 h (b) the α phase DF.

(a) a zone axis [111] bright-field image taken from the matrix of the as-quenched Fe-5Cr-0.15C alloy tempered at 120˚C for 8 h (b) the tempered martenite phase DF.

Results and Discussion

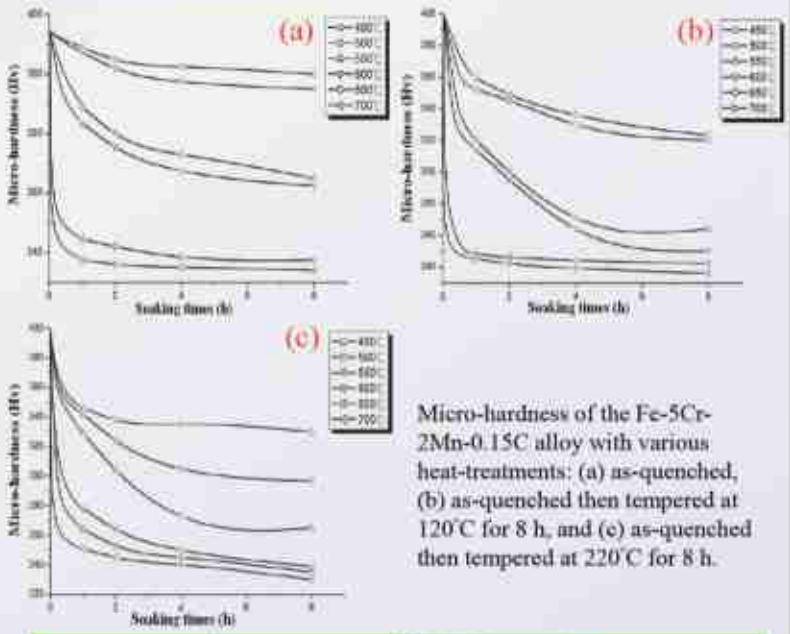

Micro-hardness of the Fe-5Cr-2Mn-0.15C alloy with various heat-treatments: (a) as-quenched, (b) as-quenched then tempered at 120˚C for 8 h, and (c) as-quenched then tempered at 220˚C for 8 h.

Heat-treatment	Mechanical properties Tensile strength (MPa)	Yield strength (MPa)	Elogation (%)
As-quenched 1100˚C–30 min	1280	1210	13.1
aging 450˚C–1.5 h	1170	1105	16.4
aging 450˚C–2.5 h	1185	1115	16.1
aging 450˚C–13.5 h	1195	1120	15.9
aging 550˚C–1.5 h	1120	1045	15.4
aging 550˚C–2.5 h	1345	1070	17.3
aging 550˚C–13.5 h	1170	1095	19.2
aging 650˚C–1.5 h	755	730	16.2
aging 650˚C–2.5 h	705	675	18.6
aging 650˚C–13.5 h	640	610	24.2



(a) a zone axis [001] bright-field image taken from the matrix of the as-quenched Fe-5Cr-2Mn-0.15C alloy tempered at 120˚C for 8 h and then aged at 650˚C for 8 h (b) the α phase DF.

Conclusion

❶The best processed condition of the Fe-5Cr-2Mn-0.15C alloy is low temperature tempering at 120oC for 8 h after solution treatment. The tensile strength 1450~1500 MPa, yield strength 1385~1440 MPa and elongation 13.5~13.7%.

❷The as-quenched Fe-5Cr-0.15C alloy tempered at 120oC for 8 h possess the maximum mechanical properties (tensile strength 1360~1365 MPa, yield strength 1250~1300 MPa and elongation 17.5~18.3%). It was found that the Fe-5Cr-0.15C alloy without Mn, the tensile strength descend is about 90~135 MPa.

❸The microstructure of alloy is mar-tempering structure by treating at 1100oC for 30 min. Its crystal structure belongs to the BCC structure t. The lattice constant is 0.287 nm.

第廿二屆第一次會員大會，論文報告評選得獎者

本期刊登 診所組前三名

第一名	梵谷美學牙醫診所	黃國光醫師、葉光大醫師
第二名	品安牙醫診所	廖謹正醫師
第三名	梵谷美學牙醫診所	黃國光醫師

預告下期刊登 醫院組前三名

第一名	長庚醫院	鄧雅音醫師、劉人文醫師
第二名	長庚醫院	何曉涵醫師、周庭安醫師、洪祥熙醫師
第三名	長庚醫院	蘇育瑩醫師、洪祥熙醫師

診所組

佳作	潔明牙醫診所	吳啟明醫師
佳作	潔明牙醫診所	吳啟明醫師

醫院組

佳作	壢新醫院	陳家進醫師、黃耀民醫師、王宏仁醫師、張雅菁醫師
佳作	國軍桃園總醫院	劉宥孛醫師、鄧德儀醫師
佳作	長庚醫院	鄧雅音醫師、何政廷醫師



植牙大探索—
打破 Sinus Lift 的迷思

林伯璣 醫師

學歷 清華大學工學士
台灣大學牙醫學士
經歷 前羅東博愛醫院牙科主任
前台大牙科兼任主治醫師
資格 中華民國齒顎矯正學會專科醫師
美國USC,UCLA 植牙專科訓練
現職 名人牙醫診所院長

INTRODUCTION

Posterior Maxilla的bone quality常不甚理想，cancellous bone的density也很低〔註1,2〕，在拔完牙或缺牙很久的posterior maxillary region，由於jaw bone的vertical resorption及maxillary sinus的pneumatic enlargement，常使其僅剩一層很薄的cortical bone和low density的cancellous bone〔註3,4〕，因此其mechanical resistance很低〔註5〕，限制了對implant的support〔註6,7,8,9〕，因而發展出sinus floor augmentation來增加vertical bone level，以利於植牙並增加其初期穩定度〔註10〕，sinus augmentation也被證明具safe procedure及predictable outcomes〔註11,12,13〕。

很多研究報告支持augmented sinus floor的bone resorption相對於non-augmented sinus floor顯得較少〔註14,15,16,17,18〕，但由於觀察時間相對較短，因此這個結論被認為沒有顯著差別。但很多學者都認為sinus floor augmentation對於改善implant bed是很成功的〔註19,20〕，特別對於atrophic jaw bone in the posterior maxilla。至於augmented materials不管是autogenous bone、HA / autogenous bone mix、HA/DFDB mix或單獨使用HA，implant survival rates均相近〔註21〕。

研究顯示由於posterior maxillary region的bone quality較差，One stage implant在non-augmentation population（crestal bone height夠，直接植牙的案例）的植牙失敗率較高〔註22,23,24,25,26,27,28〕，在augmentation population的植牙失敗率則較低，這可能是經過delayed augmentation。在植入implant之前，poorest bone volume were successfully rehabilitated；augmentation population中one stage implant甚至與two stage implant的成功率差不多〔註13〕。

不過最近十多年來，另一種理論"graft-free (graftless) sinus augmentation"也積極的發展，在Schneiderian membrane之下創造出space，但都不放任何graft materials〔註29〕或只填滿blood clot〔註30,31,32,33〕或absorbable gelatin sponge〔註34〕，都有明顯的new bone formation及不錯的stability。也有研究顯示只用"space maintaining devices"撐住sinus space， 不放任何graft materials也有成功的bone formation，目前的"space maintaining devices"有用"titanium bone fixation device"〔註35〕或"hollow HA space maintaining devices"〔註36〕。"graftfree sinus augmentation"一致的意見是Schneiderian membrane在自然下就有"innate osteogenic potential"〔註37,38,39,40,41〕。

1975年Dr. Tatum最早介紹" Crestal approach technique"〔註42〕；1980年Boyne and James 最早介紹"Lateral Window technique"〔註43〕，這兩種術式(Fig.1)各有其indication及contra-indication，並有其界定標準，也各有其支持者和愛用者，然而隨著植體設計、植牙技術和材料的演進，Sinus Lift的術式和界定標準也與時俱變，以下將做說明，但由於範圍太廣，本文將集中探討sinus lift的三大主題：

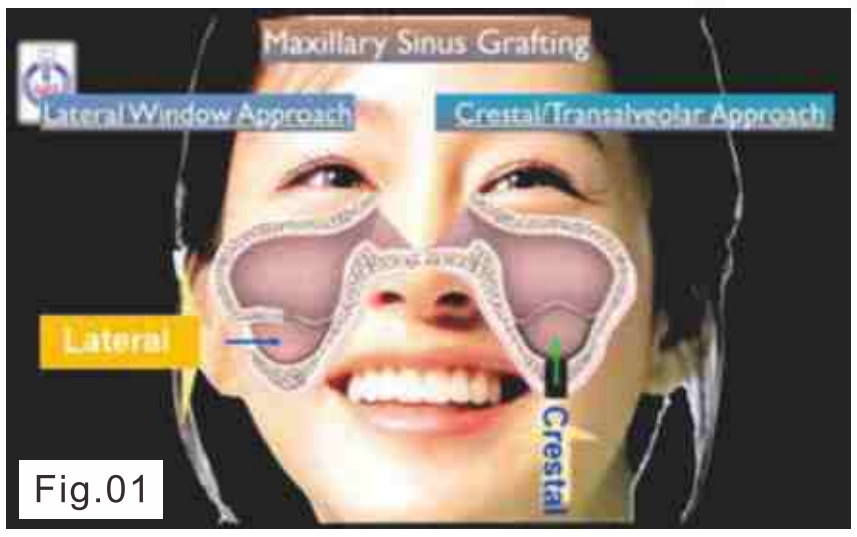

Fig.01

(1)Crest Approach的Bone Height (CBH) 限制

(2)Crest Approach的 Bone Width (CBW) 限制

(3)什麼情況需做GBR

(1)Crest Approach的Bone Height (CBH) 限制

（A）以前對使用Crest Approach術式做Sinus Lift的限制較嚴格，大都著重在Crest Bone Height (CBH)問題上(Fig.2)，當CBH>7mm時，可由crest來approach，當時主要方法是用Osteotome及sinus lift後，可直接放入植體；當CBH介於3到7mm間時，則需開側窗(lateral window)，並同時放入植體；當CBH小於3mm時，開側窗時只補骨不放植體，於二階手術條件好時再放。而不管何種情形，都需要補骨，不管是自體骨或其他filler。

（B）大約四年前，方鍾鼎醫師個人術式對此做了些修正，他將Crest Approach下修到6mm (Fig.3)，當CBH大於10mm時，用傳統方式置入植體；當CBH介於6到9mm之間時，可用osteotome手

According to Crest Bone Height

Treatment Approach Methods

CBH	Procedure	Implant	Bone graft
> 7 mm	Osteotome	with Implants	Filler
3-7 mm	Lateral W.	with Implants	Auto/Filler
< 3 mm	Lateral W.	No Implant	Auto Bone

Fig.02

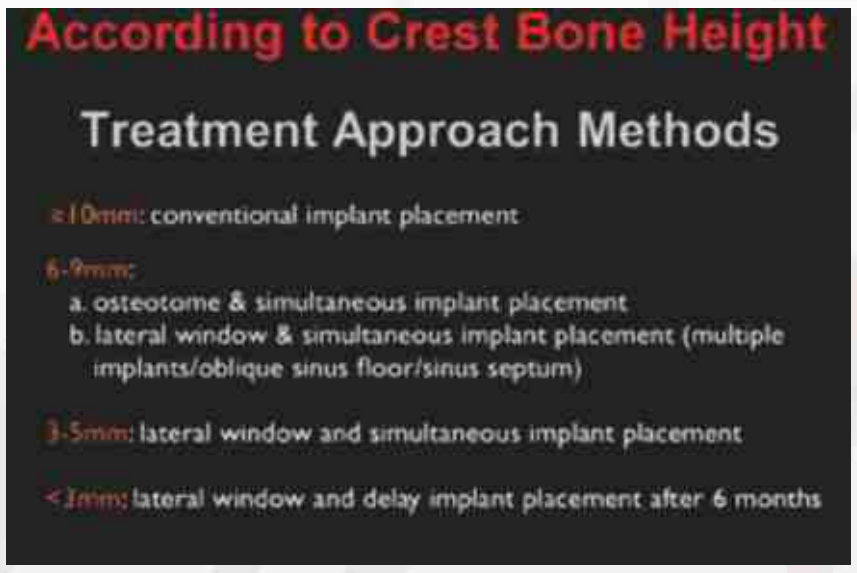

According to Crest Bone Height

Treatment Approach Methods

≥10mm: conventional implant placement

6-9mm:
a. osteotome & simultaneous implant placement
b. lateral window & simultaneous implant placement (multiple implants/oblique sinus floor/sinus septum)

3-5mm: lateral window and simultaneous implant placement

<3mm: lateral window and delay implant placement after 6 months

Fig.03

術方法，並同時置入植體；但當要置入多根植體、遇到陡峭斜坡的sinus floor 或植入位置恰好遇到septum時，他個人傾向做lateral window並同時放入植體，比較省時或簡單些。當CBH介於3到5mm間，則做lateral window並同時放入植體；當CBH 小於3mm，開lateral window並做GBR，等4到6個月後再植。

(2)Crest Approach的 Bone Width (CBW) 限制

CBW的界限，方醫師定在9mm（Fig4），當CBW大於9mm時可用crest approach，若小於9mm則用open lateral window。Dr. Samuel Lee的CBW的界限則定為10mm。至於以上Crest Bone Width (CBW)幾位大師限定為9mm或10mm，我們的研究結果如Fig.5圖示，在Crest Bone Height (CBH)不夠的條件下（6mm 左右或更小），必然考慮用短而寬的植體，以盡量增加總表面積和initial stability，因此植體可能會選擇直徑6mm或以上的植體。這時CBW就變得很重要，由於植體兩側（buccal和palatal）的bone width最好有2mm，至少也需大於1.5mm會比較理想。因此CBW最好大於9mm或10mm，甚或再寬一些更好。但由於植體設計的進步，這些限制將更寬鬆；由於有些品牌植體在Neck區做內縮(Inset)，如Fig.6,7的AnyRidge植體，直徑6到8mm 的植體neck只有4.5mm左右；直徑4到5.5mm的植體，neck區域直徑只有3.3mm左右。因此CBW 將降低，分別為7.5-8.5mm及6.5-7.5mm，條件放寬許多。

（A）Dr. Samuel Lee在2009年提出他的建議（Fig.8）：他分成四類

Class Ⅰ：CBW>10mm且CBH>7mm或CBW>12mm且CBH>6mm時，直接放入短而寬的植體，不必進行sinus lift。

Class Ⅱ：CBW>12mm且CBH>1mm時，可採用Crest Approach，他為此CBH超薄的case設計了一套專用術式和器械組。

Class Ⅲ：CBW<10mm且CBH>6mm時，採用"OsteotomeTechnique"。

Class Ⅳ：CBW<10mm且6mm>CBH>1mm時，則建議用Lateral Window technique。


According to Crest Bone Width

>10mm

- Crestal approach whenever buccal lingual width is > 9mm.
- If less than 9mm of width, then open lateral window to quickly to reduce morbidity to patients.

Fig.04

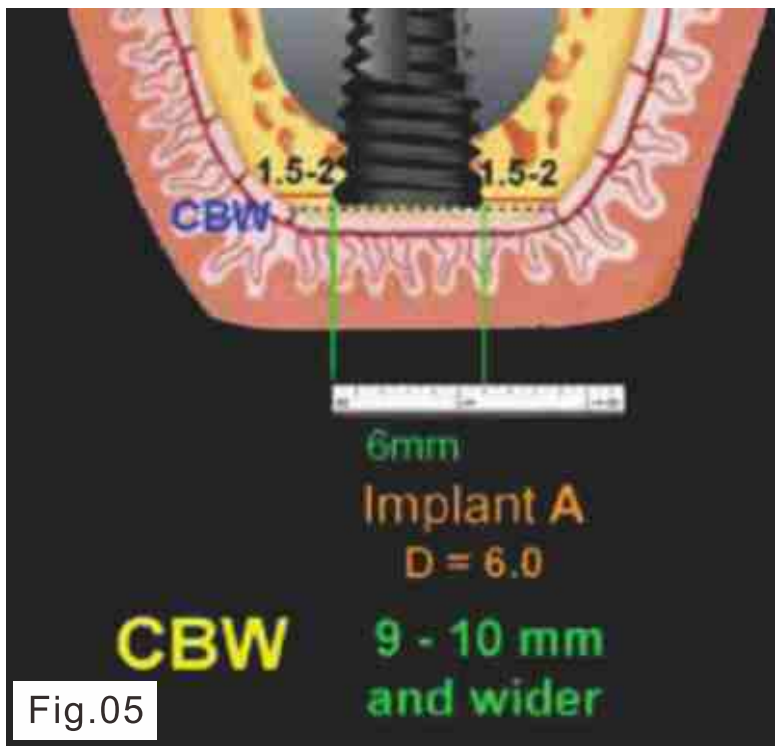

Fig.05

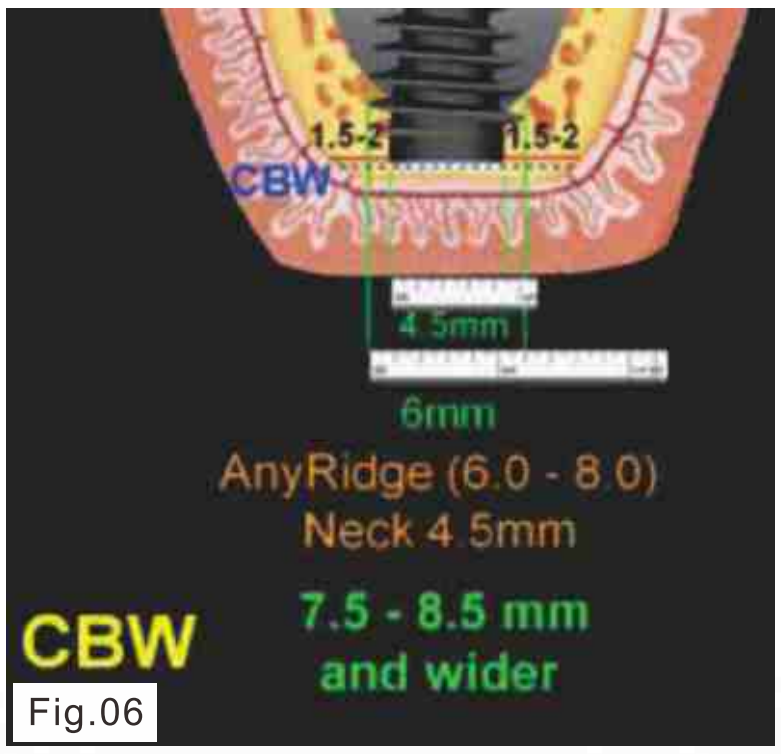

Fig.06

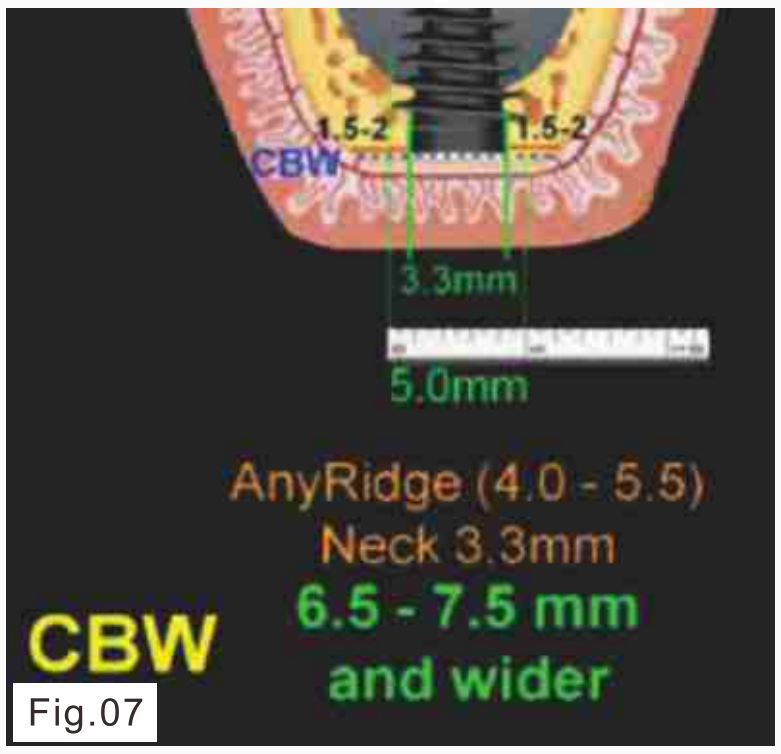

Fig.07

（B）歐亦焜醫師在2010年提出對Dr. Samuel Lee的界定標準提出修正（Fig.9），他設計出短而寬的"Taiwan Star"植體，在上顎後牙sinus區域特別好用，也更安全；而他個人也將PRF 的使用和功能發揮到極至。因此Dr. Samuel Lee所定義的Class Ⅱ、Class Ⅲ及Class Ⅳ均可由PRF的幫助，全部可用Crest Window Technique用osteotome來完成。

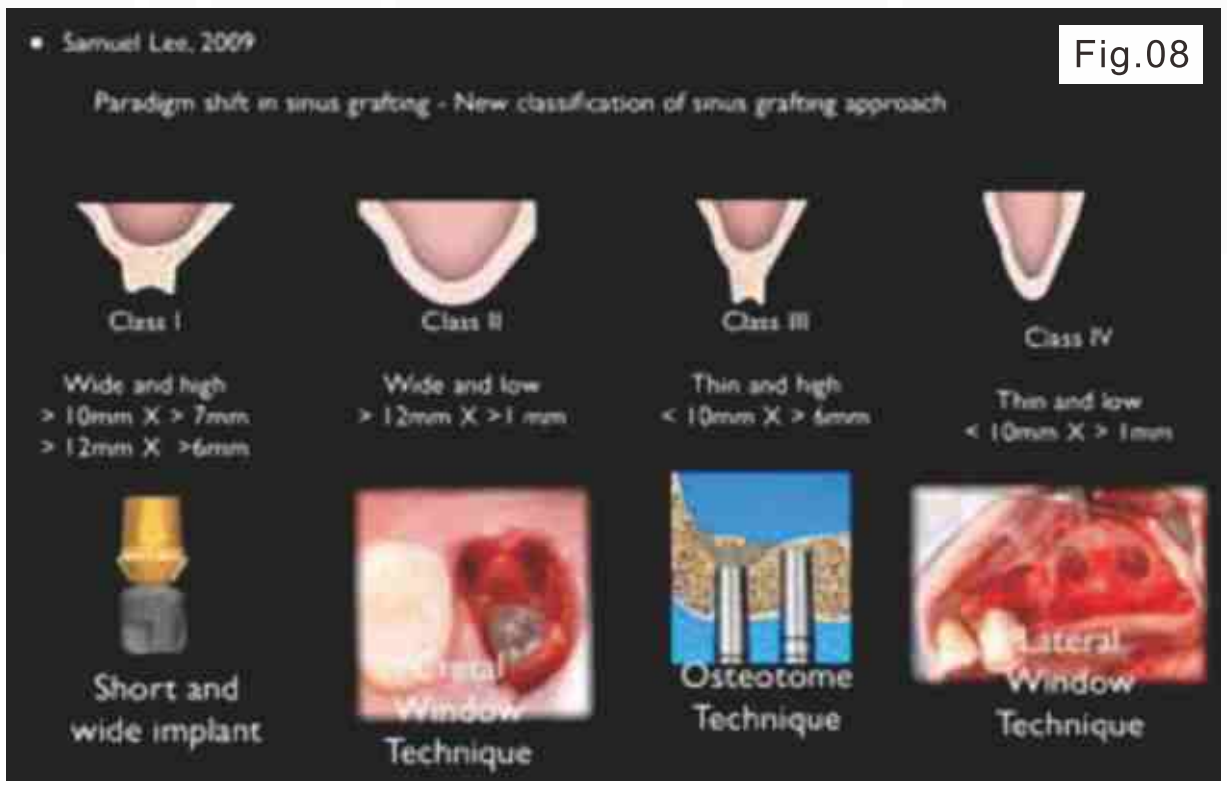

Fig.08

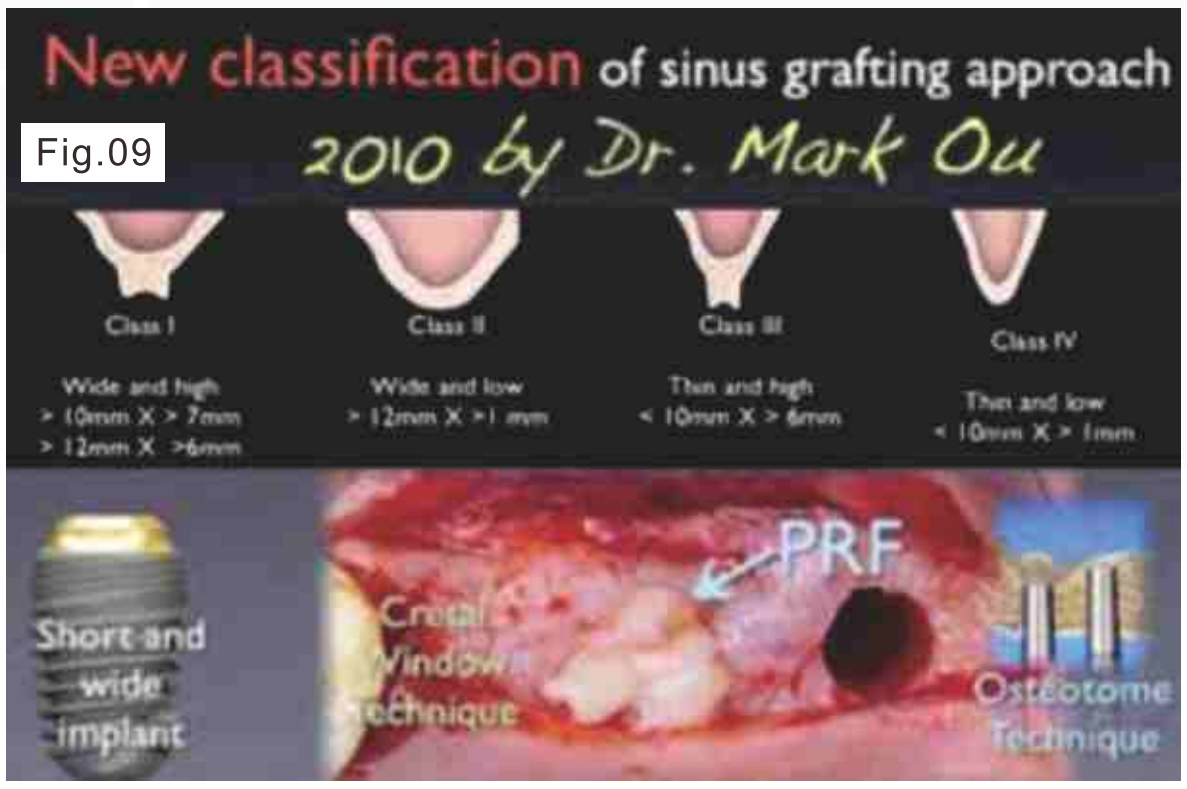

Fig.09

(3)什麼情況需做GBR

植體成功的最重要條件是兩個月內的"Stability"，植體要在安定的條件下，"osseointegration "才會完整和完成，Dr. Brunski JB 1992 年在Clinical Materials (vol 10, P153-201）提出，當植體處在受力且其位移超過100μm時，osseointegration較難完整，會有較多的可能形成fibrous-integration，使植體failure。因此sinus lift的case，當CBH夠且bone density 好，而植體伸入sinus的部份不多，且stability夠時，做不做GBR都無所謂（請參考本文案例1）。當CBH不足且bone density亦低，植體大量置入sinus內且stability不是很好時，這時就需要做GBR / GBR，其目的是要cover住其下的植體，使得來自sinus的氣壓傳到bone filler再傳到sinus floor，由sinus floor的內壁承受氣壓，不致施壓在植體上。特別是sinus內壓力大的人，如習慣用sinus共鳴唱法的歌者或京劇演員，長期身處氣壓高的高空空服員或常搭飛機旅行的人，做GBR會較安全。至於bone filler最好選擇吸收慢的，因吸收快的filler，當植體深入sinus 許多且做大量GBR的case，植入一段時間後，植體可能外露，sinus內的氣壓有可能影響osseointegration。前兩個月是長期成功與否的關鍵，至於用PRF來幫忙做sinus lift，可保護sinus membrane不受直接撞擊破裂，大大提高成功率。不過由於PRF較快被吸收，因此歐醫師在用PRF 頂上sinus membrane後，都會再做GBR，原因亦在此。

接著來探討兩個案例：

CASE REPORT

CASE 1

患者左上第一和第二大臼齒缺牙甚久，尋求植牙治療，經Pano X-ray檢查（Fig.10），發現24及25有嚴重牙周病，將Pano放大（Fig.11）後更發現24瘻管（Fistula）直通Sinus內，由於Sinus長期發炎使得內膜增生肥厚，因此建議拔除24及25，患者於四週後回來複診，拍攝口

內照片（Fig12,13）和CT（Fig.14,15），26位置的CBH為5.27mm，CBW為8.05mm；27位置的CBH為5.22mm，CBW為9.91mm。依Dr. Samuel Lee的分類均屬於Class IV，應選用Lateral Window來治療（該理論發表時MegaGen尚未研發出AnyRidge），不過我們選擇Crest Approach，並選用AnyRidge 5.5x7.0（Fig.16），其最大寬度5.5mm，其實際長度為7.0-1.0=6.0mm，屬於螺紋極深的短植體，因此可緊緊的咬住骨頭，且具tapering形狀，在由crest做sinus lift時很安全。在prepared時發現骨頭極軟，屬於D4 bone（Fig.17），依據我們的法則（Fig.18），D4 bone的final drill會選用小3-4號的drill，寬5.5mm的植體小4號的drill為2.9mm（Fig.19），植完26後再植27（Fig.20）：測26位置之ISQ值為66；而27位置則僅有57（Fig.21），為了安全考量，我們選用Healing abutment，術後照CT和Pano（Fig.22,23），兩個月後再測ISQ分別增加到72和65，因此我們為患者裝上provisional crowns，5個月後再測又增為81和75。將pano（Fig.23）上的植體區放大（Fig.24），將植體照片superimpose上去並描出sinus walls（Fig.25），將27部位放大（Fig.26）發現植體深入sinus內腔平均有1.6mm，扣除平面式的neck區1mm，具螺紋實質有嵌入bone內的部位平均長度只有3.4mm，bone density又屬於D4（Fig27），且本案例並沒有做GBR，因此沒有bone filler幫忙固定植體，因此sinus內的氣壓將直接影響植體！但經驗告訴我們，5.5x7.0的AnyRidge即使只有3.4mm卡住bone，由於螺紋相當深，即使骨質鬆軟，螺紋的"mechanic lock"也會緊緊的咬住bone，使得植體獲得很好的stability，得以在安定的環境下進行骨整合。深螺紋使得短植體也能擁有很大的表面積，在骨整合完成後，有足夠的retention來提供咬合，因此兩個月內ISQ數值由57增加到65，五個月後更增加到75，顯示骨整合相當成功！


Fig.10


Fig.11


Fig.12


Fig.13

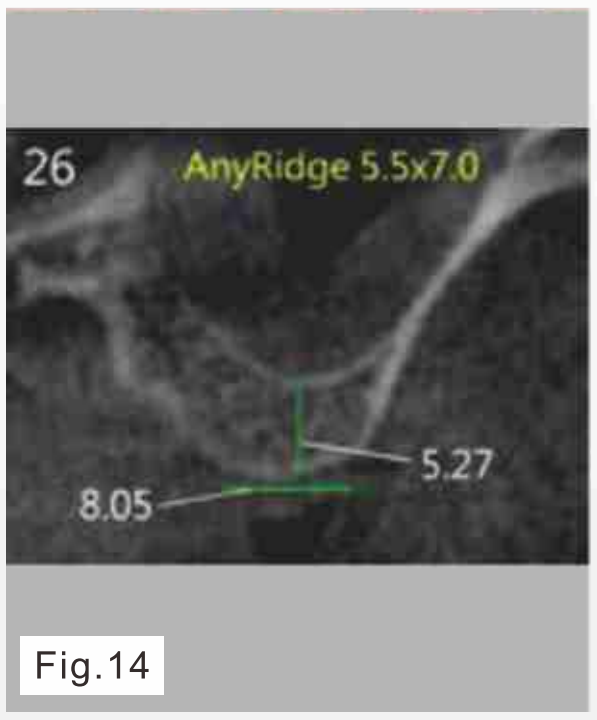
Fig.14

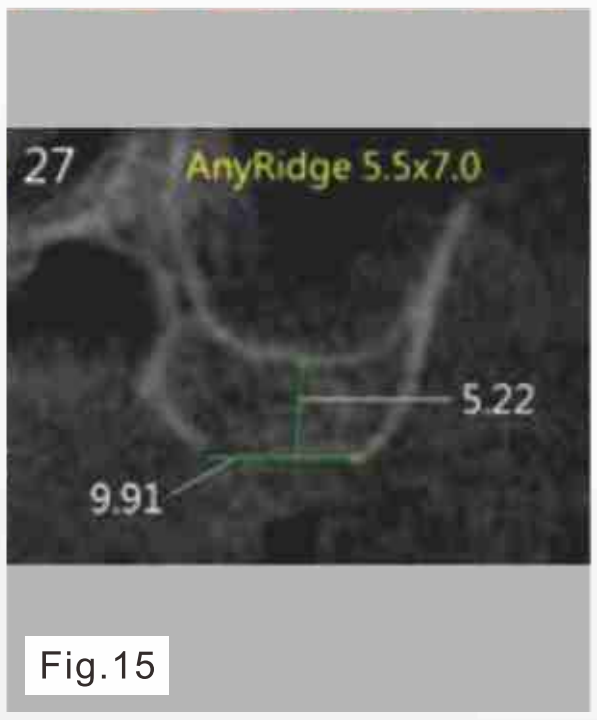
Fig.15


Fig.16


Fig.17

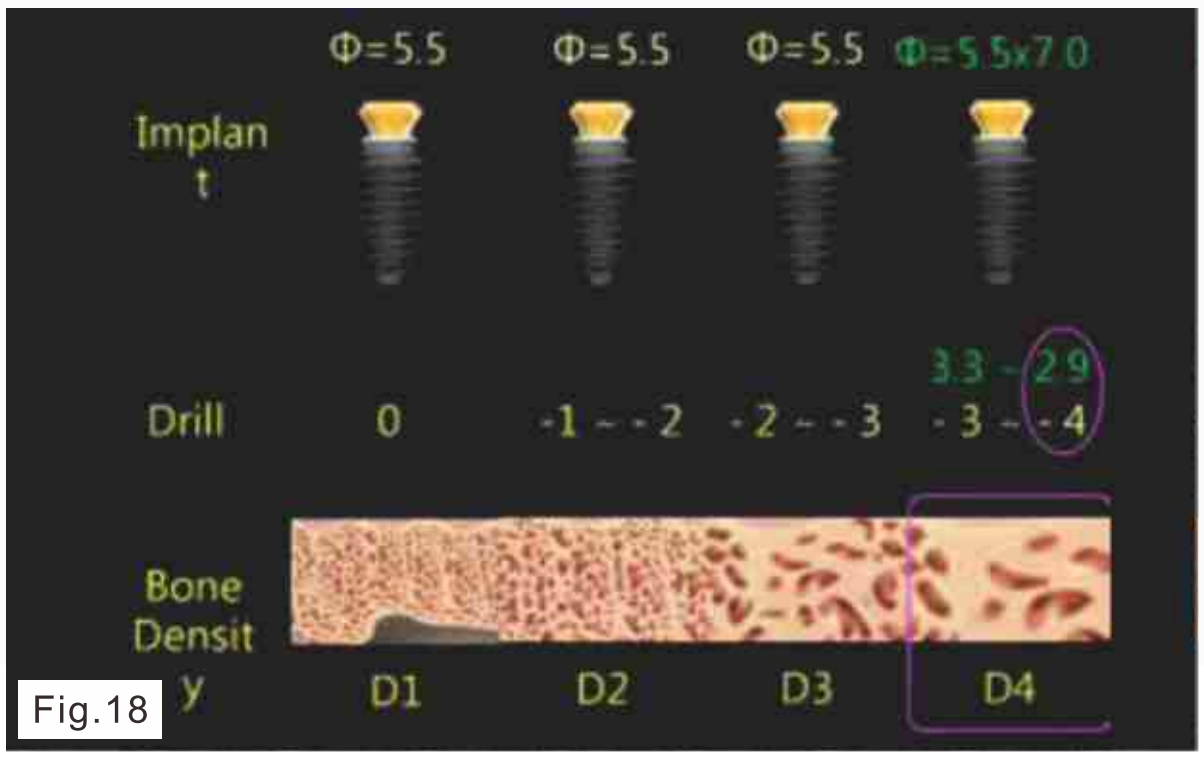
Fig.18


Fig.19


Fig.20


Fig.21

ISQ	2 mo	5 mo
26 66	→ 72	→ 81
27 57	→ 65	→ 75
Healing Abutment	Provisional Crowns	

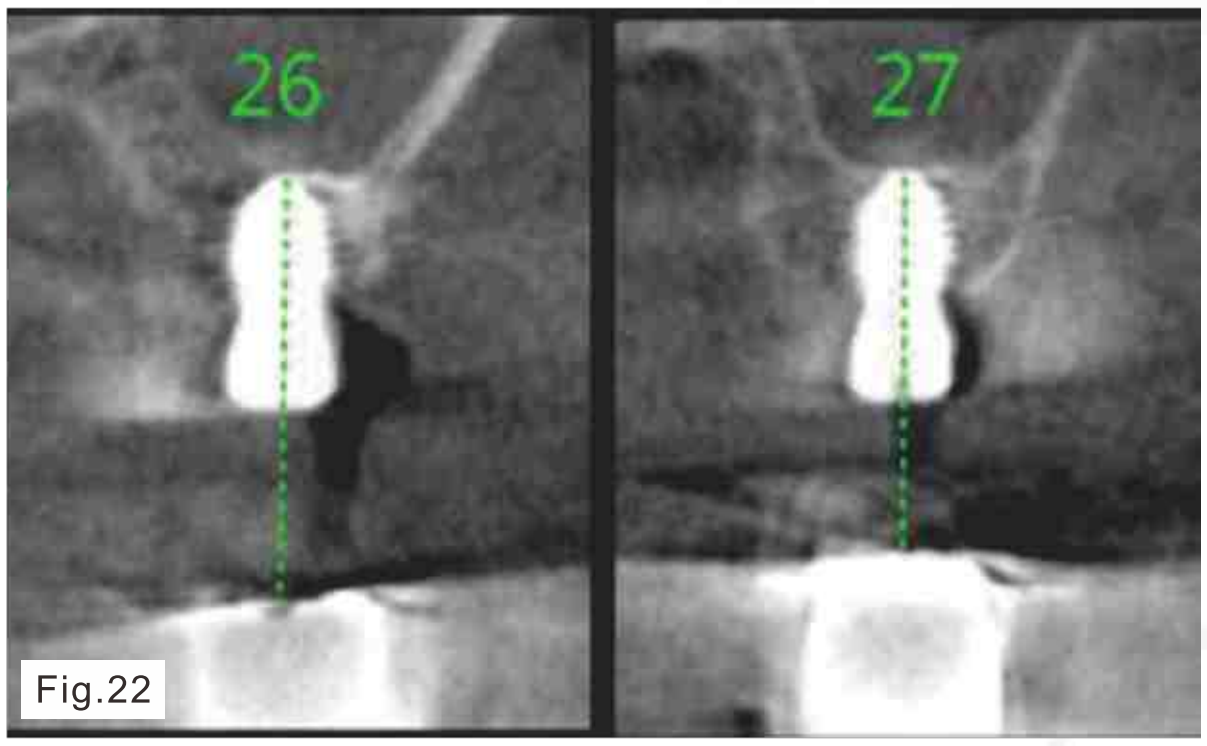
Fig.22


Fig.23


Fig.24


Fig.25

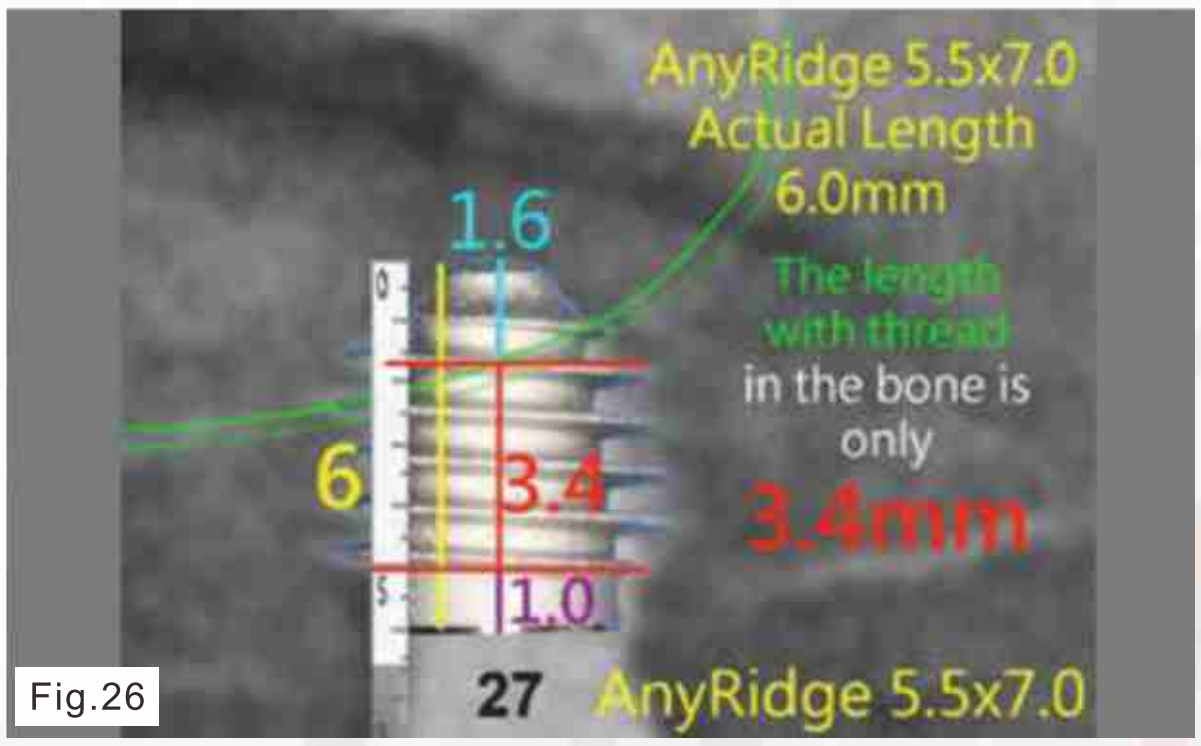
Fig.26

AnyRidge 5.5x7.0 Actual Length 6.0mm

The length with thread in the bone is only 3.4mm

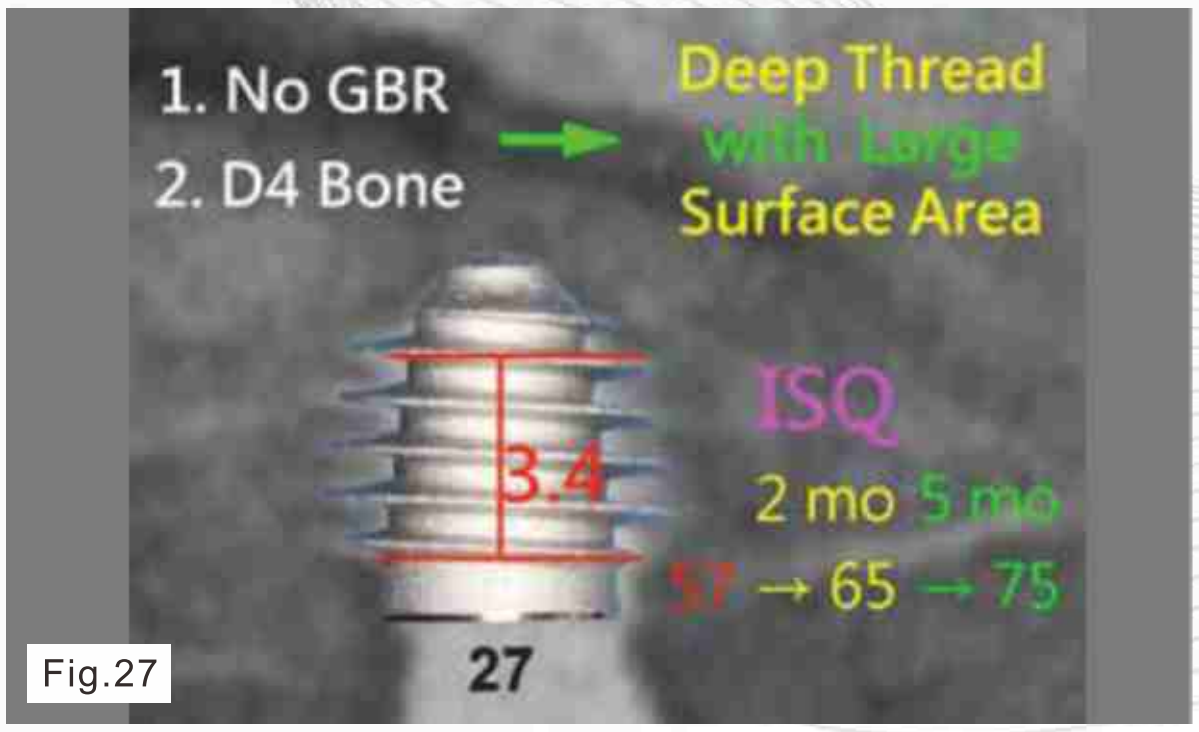

Fig.27

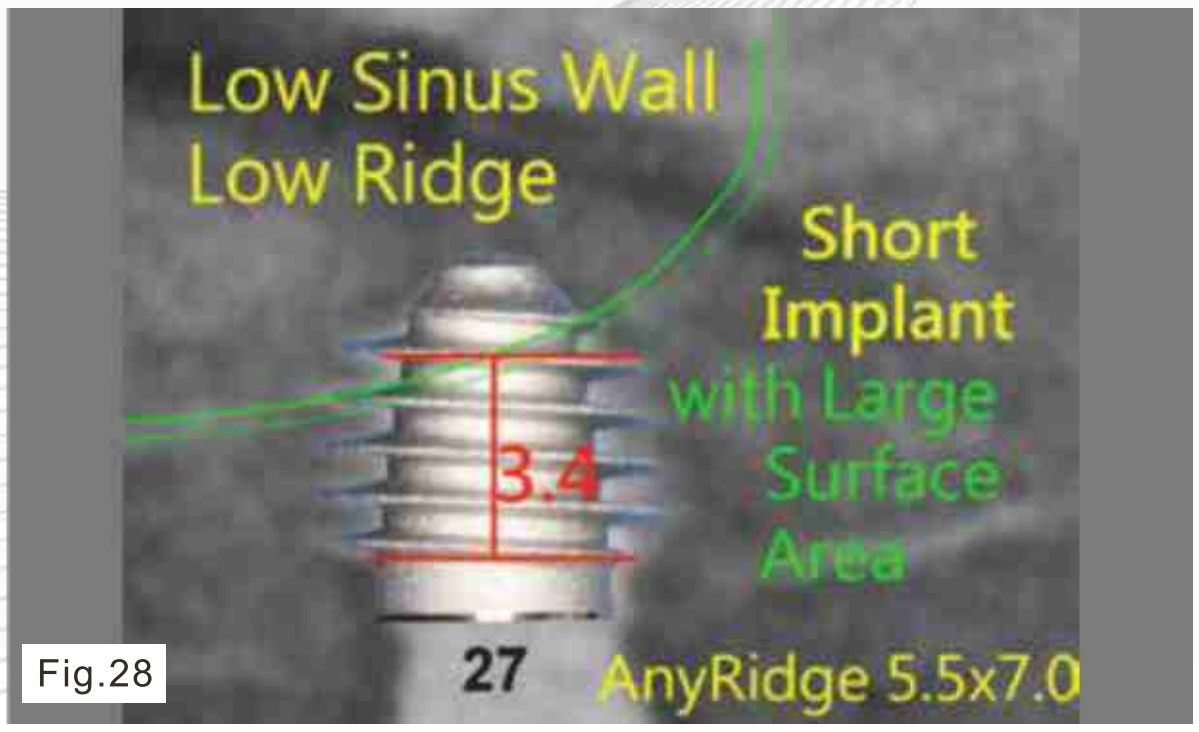

Fig.28

本案例說明 Sinus Lift 三件事：

1. 只要Stability足夠，沒做GBR骨整合也能成功。
2. 只要Sinus Membrane Intact植體不受感染，骨整合就會在sinus內自然發生。
3. 具有大表面積的短植體，未來對"Low Sinus Wall"和"Low Ridge"的cases，將扮演很重要的角色（Fig.28）

CASE 2

患者右上第一及第二大臼齒（16,17）兩個月前被拔除（Fig.29,30），患者求診要求植牙治療。

Fig.29

Fig.30

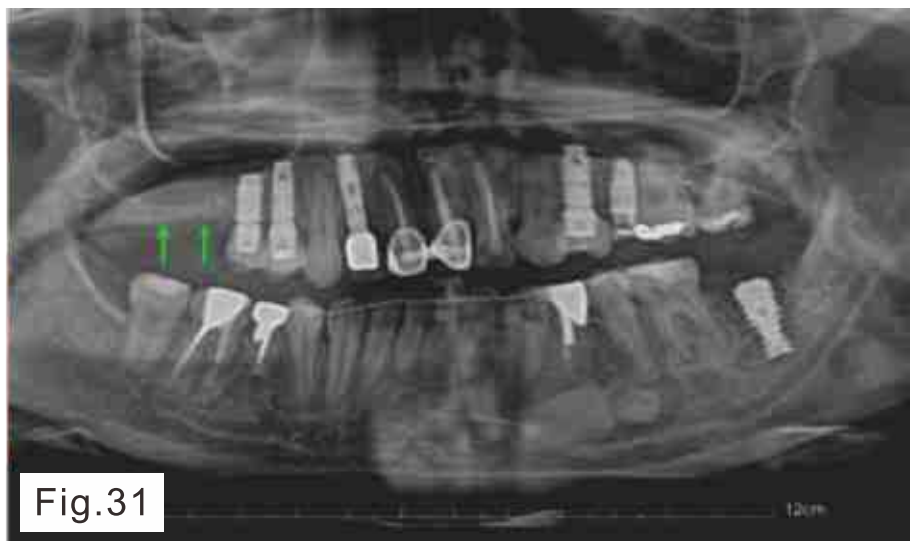

Fig.31

Pano影像經放大並描出（Fig.31,32,33）顯示CBH極小，16位置的CT經描圖並測量後（Fig.34,35,36），CBH只有2.96mm，CBW 也只有 6.5mm，17位置的CT經描出並測量（Fig.37,38,39,40），CBH的值為 2.35mm，而CBW則為 9.27mm，我們先用Trephine Bur（Fig.41），再用 Osteotome做 sinus lift，GBR後放入植體（Fig.42,43），16植入 AnyRidge 4.5x8.5mm，17植入 5.0x8.5mm（Fig.43），植完後測ISQ，16值為 68，17值為 66，由於兩者的CBH均小於 3mm，因此螺紋必須放在骨頭裡，平面式的Neck（Fig.44綠色箭頭處）則使之外露（Fig.45綠色箭頭處），植完鎖上cover screw（Fig.46），flap suture起來（Fig,47）。術後照CT（Fig,48），看得到GBR做得很完整，這案例 26和 27是新拔牙區，crest bone的radiopaque不明顯，CBH低，植體大部份伸入sinus內，stability在前幾個月可能不夠，因此我們認為必須做GBR，以避免氣壓干擾骨整合，五個月後測ISQ，16及 17值均為 78（Fig,49），接上 fuse abutment，照CT並與五個月前影像進行比較（Fig.50,51,52），由Pano及Periapical之 X ray來看（Fig,53,54），可以發現骨整合相當成功！（Fig.55,56 是完成後的口內相片）


Fig.32


Fig.33

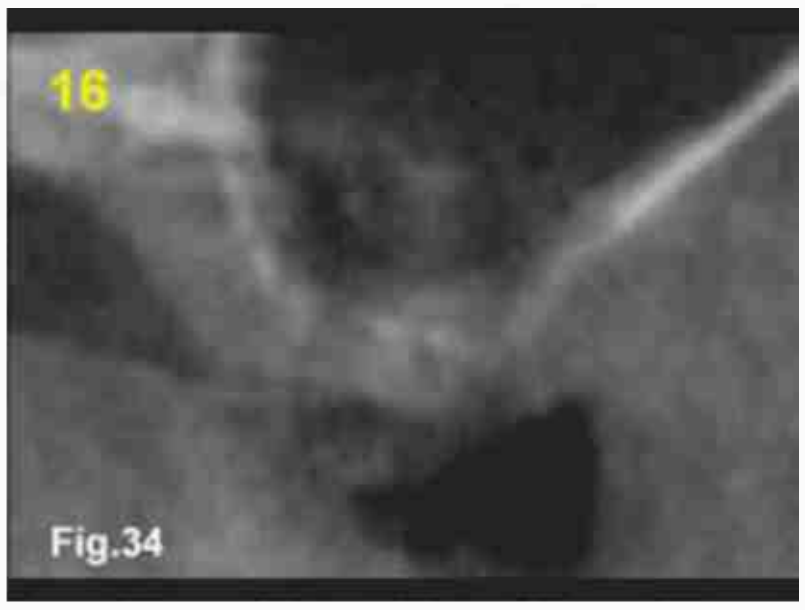

Fig.34

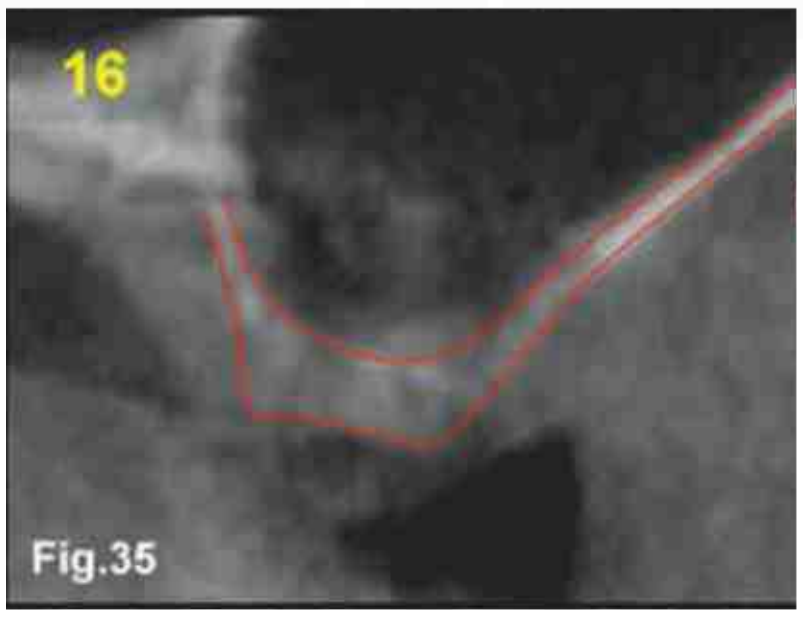

Fig.35

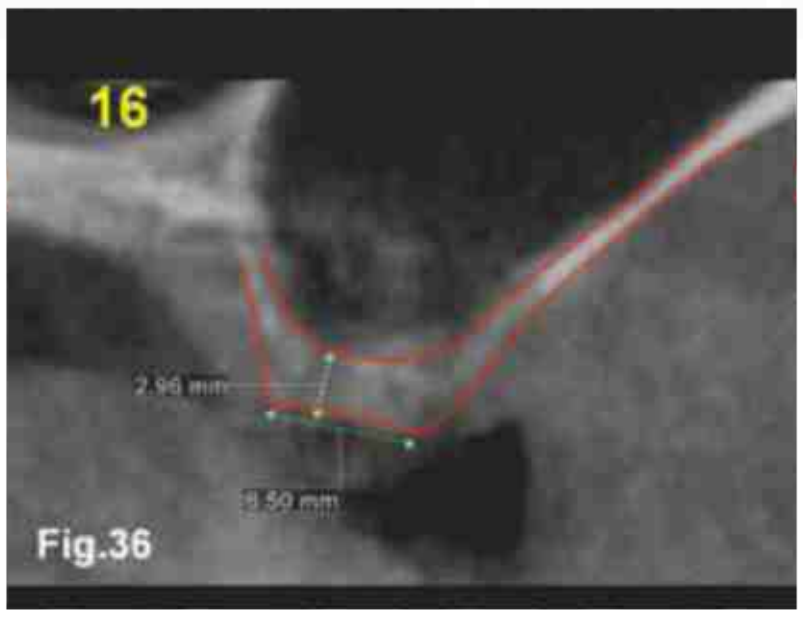

Fig.36

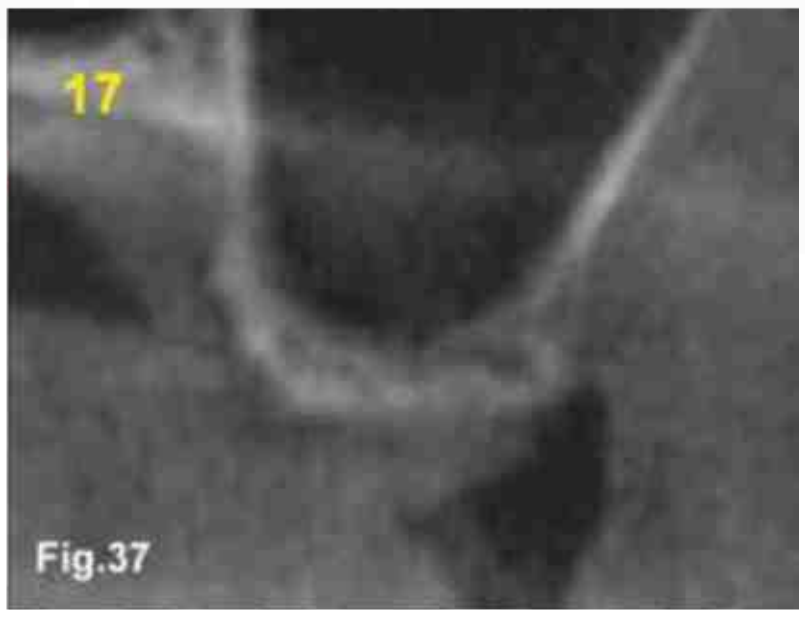

Fig.37

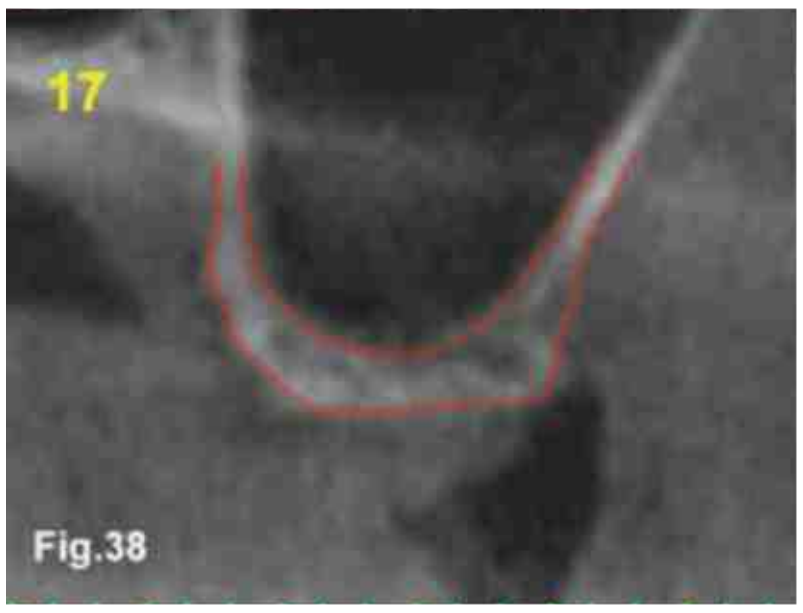

Fig.38

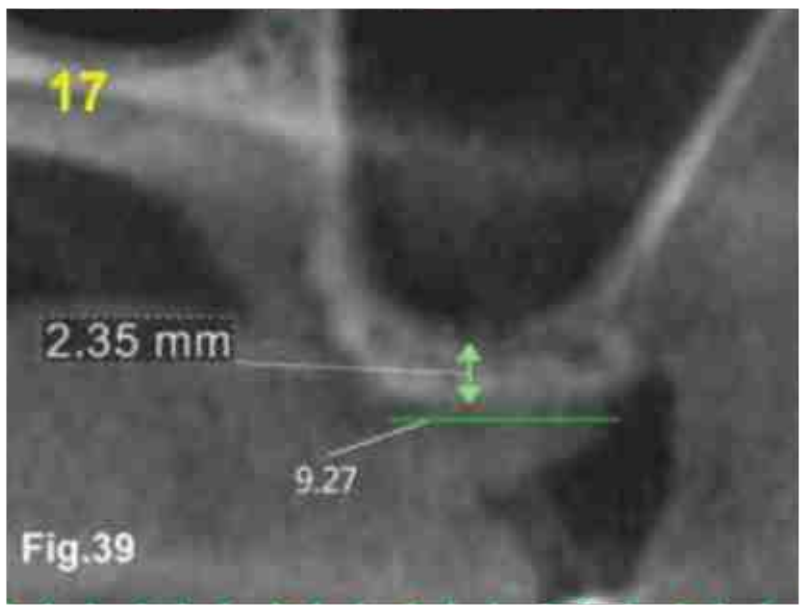

Fig.39

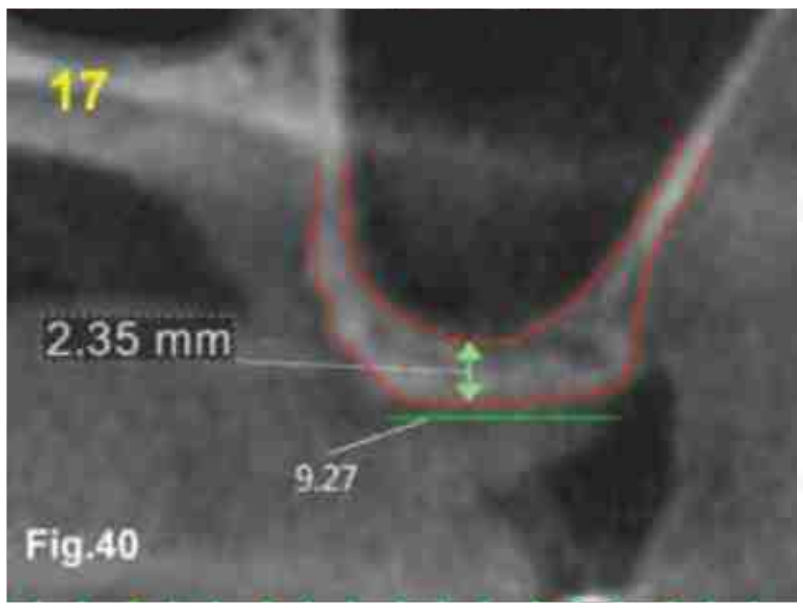

Fig.40


Fig.41

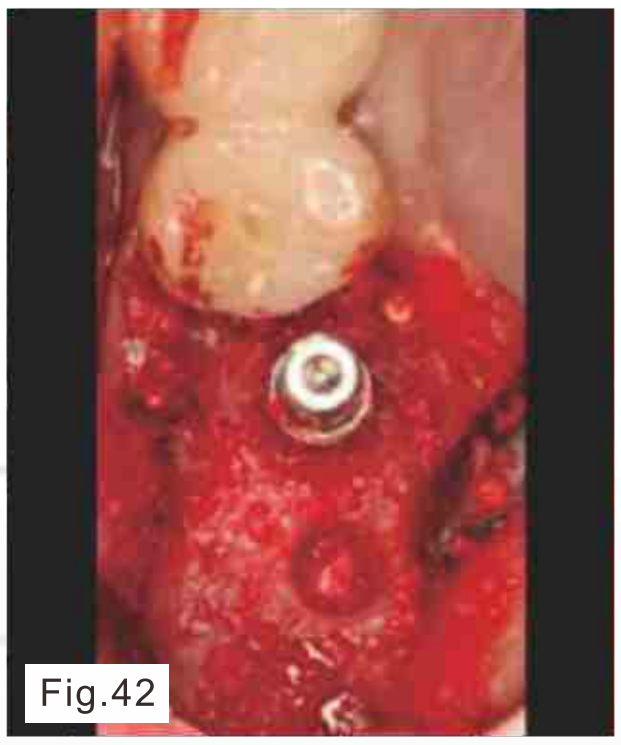
Fig.42

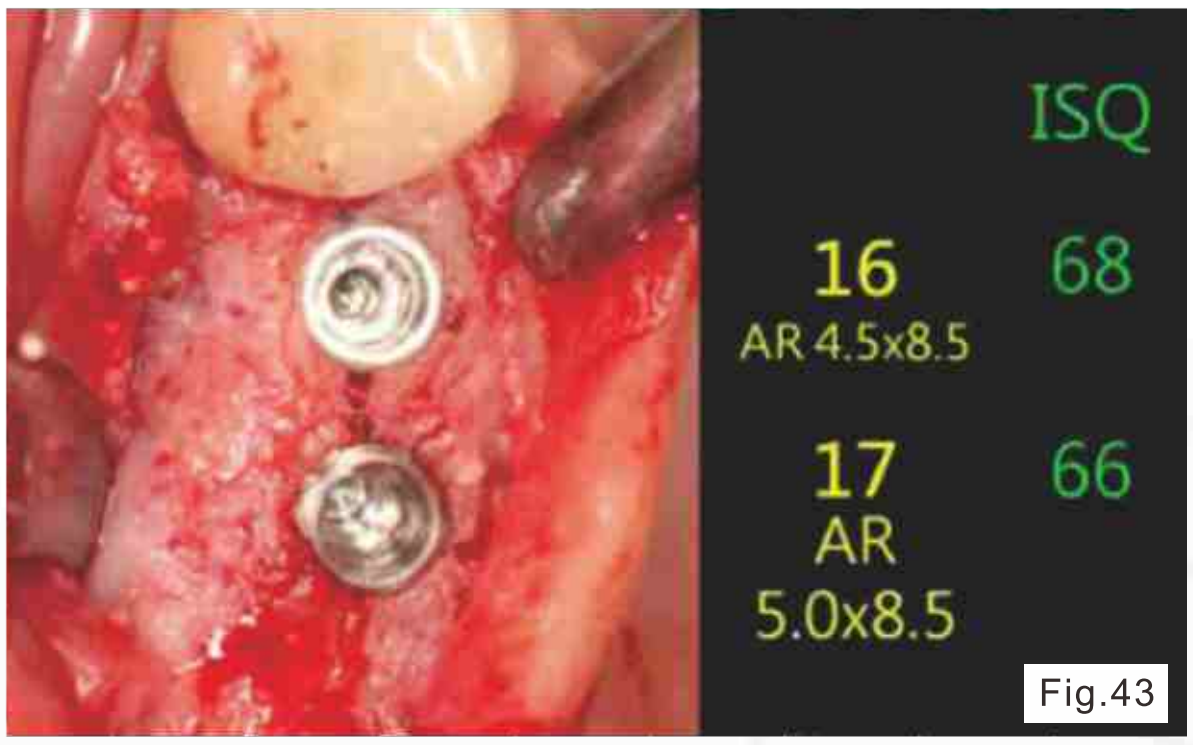

Fig.43

Fig.44

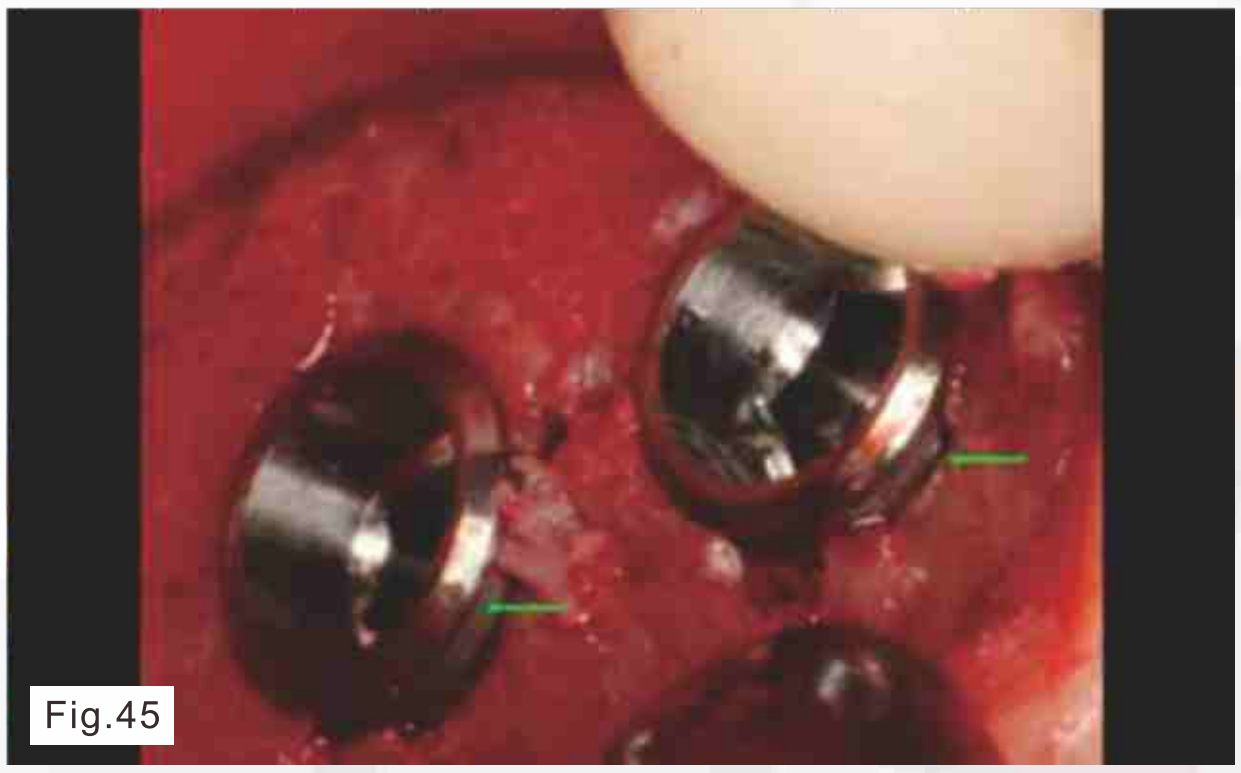
Fig.45

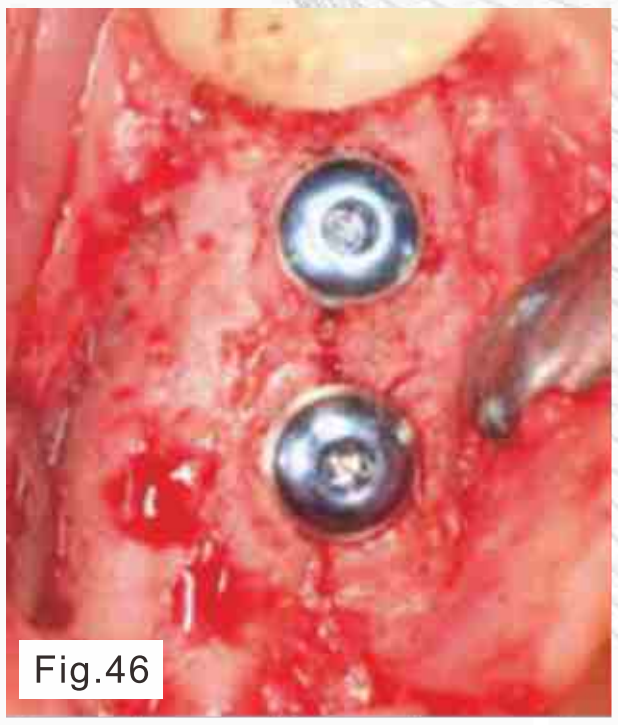
Fig.46


Fig.47

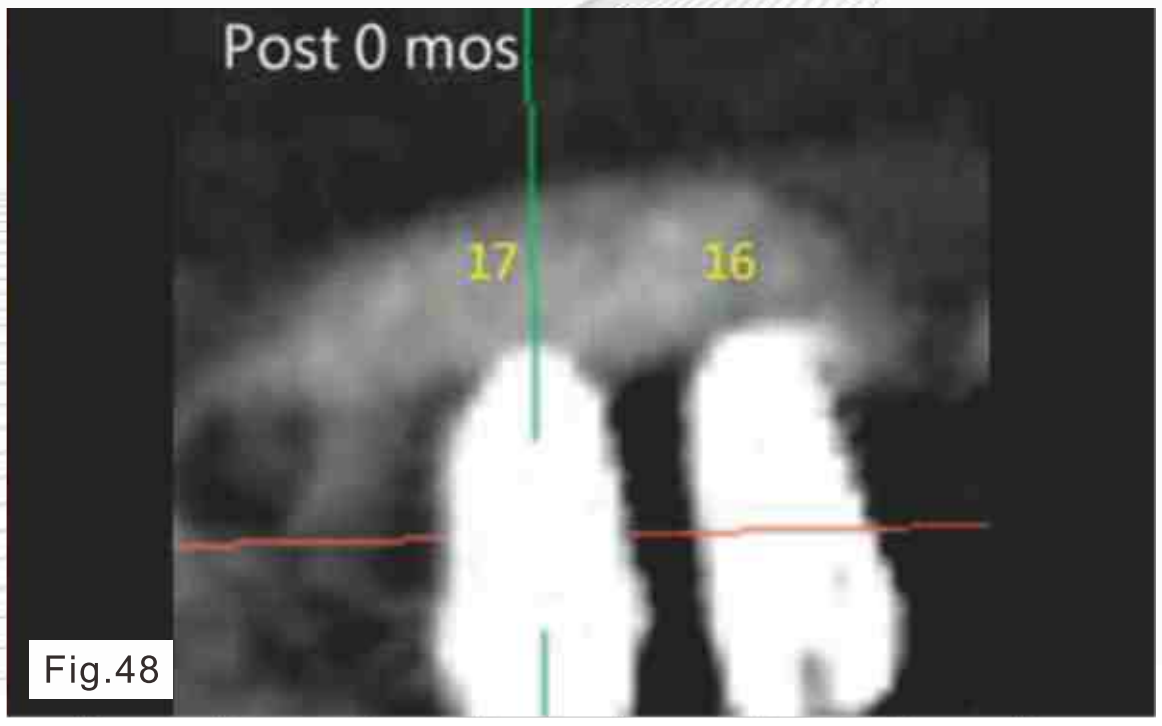

Fig.48

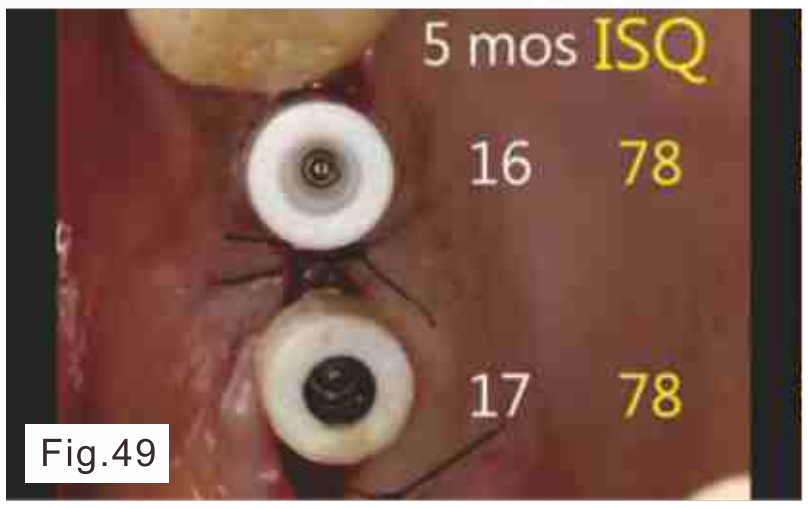

Fig.49

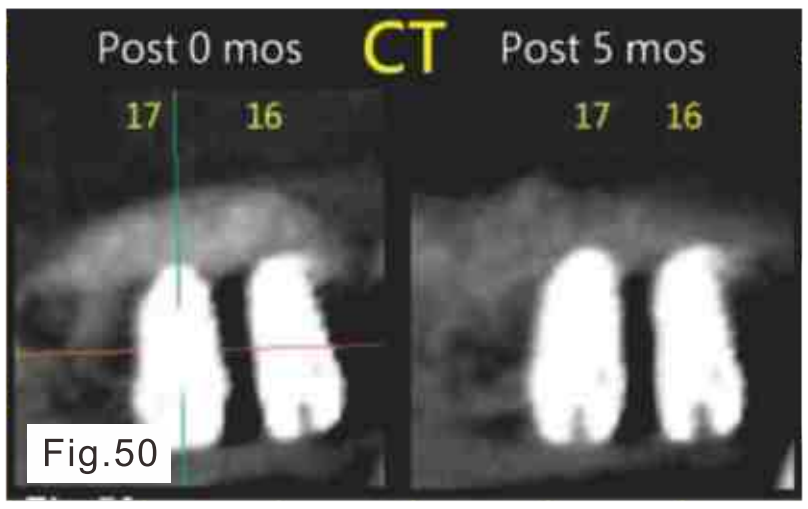

Fig.50

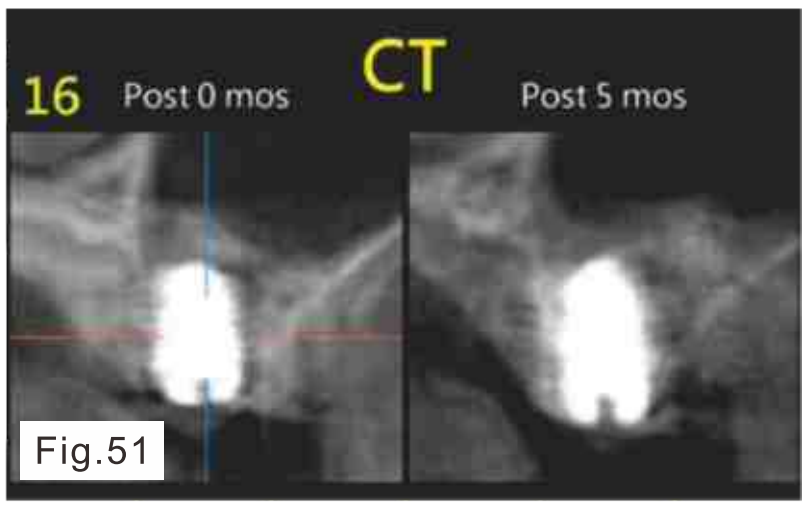

Fig.51

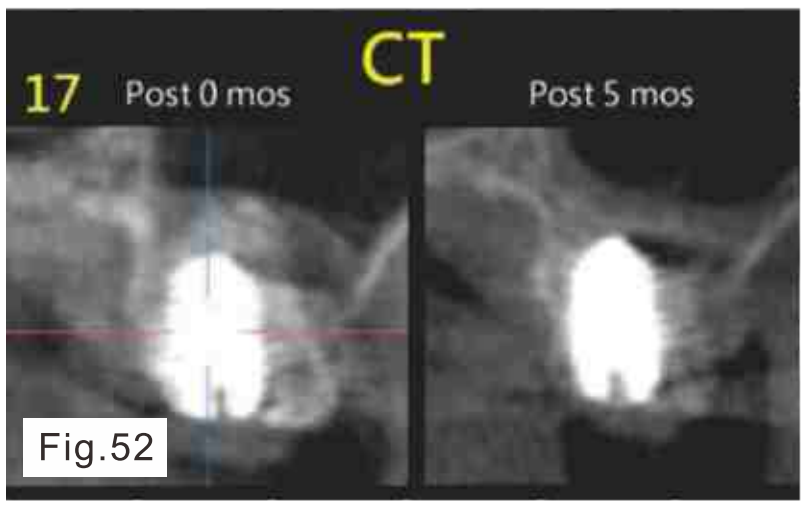

Fig.52


Fig.53

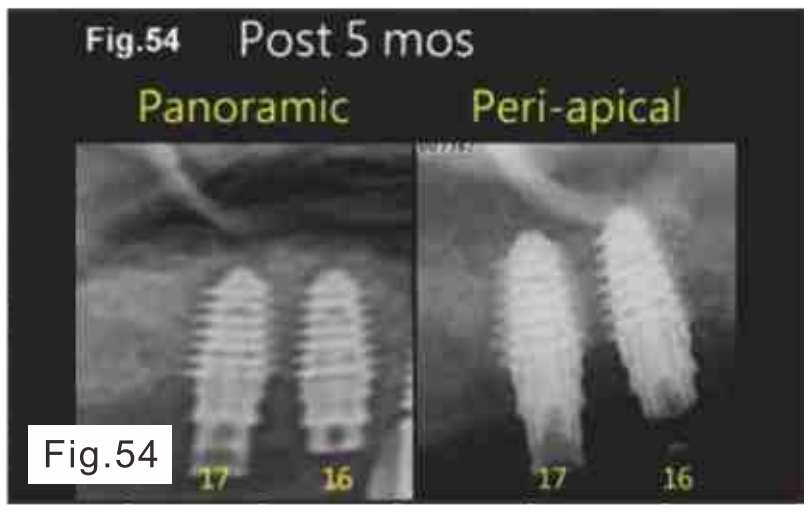

Fig.54

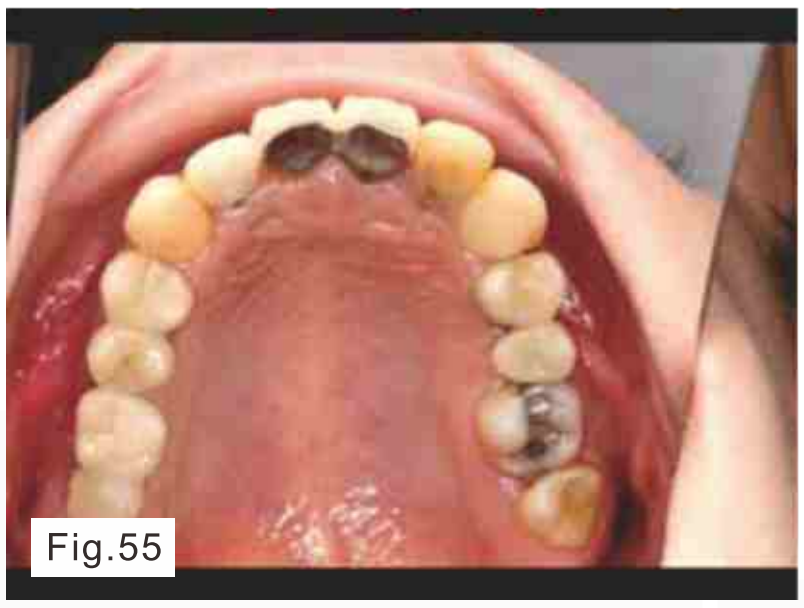
Fig.55


Fig.56

由這兩個案例和過往經驗， 我們給Sinus Lift定下新的Criteria：

1. Crest Approach將無Crest Bone Height的限制。
2. Crest Bone Width在CBH小於6mm下可降低到6.5mm。
3. 植完兩個月內的預估Stability決定GBR的必要性。

REFERENCES

1.Misch CE.Density of bone:Effect on treatment plans,surgical approach, healing and progressive bone loading Int J Oral Implantol 1990;6:23–31.

2.Wheeler SL,Holmes RE,Calhoun CJ. Six-year clinical and histologic study of sinus-lift grafts. Int J Oral \ Maxillofac Implants 1996;11:26–34.

3.Tidwell JK,BlijdorpPA,Stoelinga PJ,Brouns JB,Hinderks F.Composite grafting of endosteal implants.A preliminary report of 48 patients. Int J Oral Maxillofac Surg 1992;21:204–209.

28.Jaffin R, Berman C. The excessive loss of Brånemark fixtures in type IV bone. A 5-year analysis. J Periodontol 1991;62:2-4

29.Maxillary Sinus Augmentation as a Risk Factor for Implant Failure Lundgren S, Andersson S, Sennerby L. Spontaneous bone formation in themaxillary sinus after removal of a cyst: coincidence or consequence? Clin Implant Dent Relat Res. 2003;5(2):78-81. [Medline: 14536041][doi: 10.1111/j.1708-8208.2003.tb00187.x]

4.Tatum H Jr. Maxillary and sinus implant reconstructions. Dent Clin North Am. 1986 Apr;30(2):207-29.[Medline : 3516738]

5.Graziani F, Donos N, Needleman I, Gabriele M,Tonetti M.Comparison of implant survival following sinus floor augmenta-tion procedures with implants placed in pristine posterior maxillary bone : A systematic review. Clin Oral Implants Res 2004;15:677–682.

6.Cawood JI, Howell RA.A classification of the edentulous jaws. Int J Oral Maxillofac Surg 1988;17:232-236.

7.Chanavez M.Maxillary sinus: Anatomy,physiology, surgery and bone grafting related to implantology. Eleven years of surgical experience(1979-1990). J Oral Implantol 1990;16:199-209.

8.Tatum H. Maxillary and sinus implant reconstructions. Dent Clin North Am 1988;30:207229.

9.Ulm CW, Solar P, Gsellmann B, Matejka M, Watzek G. The edentulous maxillary alveolar process in the region of the maxillary sinus—A study of physical dimensions. Int J Oral Maxillofac Surg 1995;24;279-282.

10.Tatum H. Maxillary and sinus implant reconstructions. Dent Clin North Am 1986;30:207–229.

11.Adell R, Lekholm U, Grondahl K, Brånemark P-I, Lindstrom J,Jacobsson M. Reconstruction of severely resorbed edentulous maxillae using osseointegrated fixtures in immediate autoge-nous bone grafts. Int J Oral Maxillofac Implants 1990;5:233–246.

12.Raghoebar GM, Vissink A, Reintsema H, Batenburg RH. Bone grafting of the sinus floor of the maxillary sinus for the place-ment of endosseous implants. Br J Oral Surg 1997;35:119–125.

13.Mcdermott NE,Chung SK,Woo VV,Dodson TB. Maxillary sinus augmentation as a Risk Factor for implant failure.Int J Oral Maxillofac Implants! 2006;21:366-374.

14.Watzek G, Weber R, Bernhart T, Ulm C, Haas R. Treatment of patients with extreme maxillary atrophy using sinus floor augmentation and implants: Preliminary results. Int J Oral Maxillofac Surg 1998;27:428–434.

15.Raghoebar GM, Brouwer TJ, Reintsema H, van Oort RP. Augmentation of the maxillary sinus floor with autogenous bone for the placement of endosseous implants: A preliminary report. J Oral Maxillofac Surg 1993;51:1198–1203.

16.Schlegel KA, Schultze-Mosgau S, Wiltfang J, Neukam FW, Rupprecht S, Thorwarth M. Changes of mineralization of free autogenous bone grafts used for sinus floor elevation. Clin Oral Implants Res 2006;17:673–678.

17.Schlegel KA, Fichtner G,Schultze-Mosgau S, Wiltfang J. Histologic findings in sinus augmentation with autogenous bone chip sversus a bonine bone substitute. Int J Oral Maxillofac Implants 2003;18:53–58.18.

18.Schlegel KA, Huberts S, Kastner C. Verlustrate von Brånemark-Fixturen mit unterschiedlicher prothetischer Nutzung. Dent Implantol 1998;2:86–99.

19.Smiler DG, Johanson PW, Lozada JL, Misch C, Rosenlicht JL,Tatum OH Jr. Sinus lift grafts and endosseous implants. Treatment of the atrophic posterior maxilla. Dent Clin North Am 1992;36:151–186.

20.Jensen J, Sindet-Pedersen S, Oliver AJ. Varying treatment strategies for reconstruction of maxillary atrophy with implants:Results in 98 patients. J Oral Maxillofac Surg 1994;52:210–216.

21.Tong Dc,Rioux K,Drangsholt M,Beirne OR. A Review of Survival Rates for Implants Placed in Grafted Maxillary Sinuses Using Metaanalysis.Int J Oral Maxillofac Implants 1998;13:175-182

22.Olsen JW, Dent DC, Morris HF, Ochi S.Long term assessment(5 to 71 months) of endosseous dental implants placed in the augmented maxillary sinus. Ann Periodontol 2000;5:152-156.

23.Vehemente VA, Chuang Sk, Daher S Muftu A, Dodson TB. Risk factors affecting dental implant survival. J Oral Implantol 2002;28:74-81.

24.Bain CA, Moy PK. The association between the failure of dental implants and cigarette smoking. Int J Oral Maxillofac Implants 1993;8:609-615.

25.Jensen OT, Shulman LB, Block MS, Iacono VJ. Report of the sinus consensus conference of 1996. Int J Oral Maxillofac Implants 1998;13(suppl):11-45.

26.Kan JYK, Rungcharassaeng K, Kim J, Lozada J, Goodacre CJ.Fac-tors affecting survival of implants placed in grafted maxillary sinuses: A clinical report. J Prosthet Dent 2002;87:485-489.

27.Friberg B, Jemt, T, Lekholm U. Early failures in 4641 consecutively installed Brånemark implants. A study from stage-one surgery to connection of complete prostheses. Int J Oral Maxillofac Implants 1991;6:142-146.

30.Lundgren S, Andersson S, Sennerby L. Spontaneous bone formation in themaxillary sinus after removal of a cyst: coincidence or consequence? Clin Implant Dent Relat Res. 2003;5(2):78-81. [Medline: 14536041][doi: 10.1111/j.1708-8208.2003.tb00187.x]

31.Chen TW, Chang HS, Leung KW, Lai YL, Kao SY. Implant placement immediately after the lateral approach of the trap door window procedure to create a maxillary sinus lift without bone grafting: a 2-year retrospective evaluation of 47 implants in 33patients. J Oral Maxillofac Surg. 2007 Nov;65(11):2324-8. [Medline:17954333] [doi: 10.1016/j.joms.2007.06.649]

32.Hatano N, Sennerby L, Lundgren S. Maxillary sinus augmentation using sinus membrane elevation and peripheral venous blood for implant-supported rehabilitation of the atrophic posterior maxilla: case series. Clin Implant Dent Relat Res. 2007 Sep;9(3):150-5. [Medline: 17716259] [doi: 10.1111/j.1708- 8208.2007.00043.x]

33.Moon JW, Sohn DS, Heo JU, Shin HI, Jung JK. New bone formation in the maxillary sinus using peripheral venous blood alone. J Oral Maxillofac Surg. 2011 Sep;69(9):2357-67. Epub 2011 Jun 30. [Medline: 21719179] [doi: 10.1016/j.joms.2011.02.092]

34.Sohn DS, Lee JS, Ahn MR, Shin HI. New bone formation in the maxillary sinus without bone grafts. Implant Dent. 2008 Sep;17(3):321-31. [Medline: 18784532] [doi: 10.1097/ID.0b013e318182f01b] !

35.Kaneko T, Masuda I, Horie N, Shimoyama T. New bone formation in nongrafted sinus lifting with spacemaintaining management: a novel technique using a titanium bone fixation device. J Oral Maxillofac Surg. 2012 Mar;70(3):e217-24.[Medline: 22374065] [doi: 10.1016/j.joms.2011.10.025]!

36.Johansson LÅ, Isaksson S, Adolfsson E, Lindh C, Sennerby L.Bone regeneration using a hollow hydroxyapatite space-maintaining device for maxillary sinus floor augmentation--a clinical pilot study.Clin Implant Dent Relat Res. 2012 Aug;14(4):575-84. Epub 2010 Jun 2. [Medline: 20586781] [doi:10.1111/j.1708- 8208.2010.00293.x]

37.Bell GW, Joshi BB, Macleod RI. Maxillary sinus disease:diagnosis and treatment. Br Dent J. 2011 Feb 12;210(3):113-8.[Medline: 21311531] [doi: 10.1038/sj.bdj.2011.47]!

38.Chen TW, Chang HS, Leung KW, Lai YL, Kao SY. Implant placement immediately after the lateral approach of the trap door window procedure to create a maxillary sinus lift without bone grafting: a 2-year retrospective evaluation of 47implants in 33 patients. J Oral Maxillofac Surg. 2007 Nov;65(11):2324-8. [Medline: 17954333] [doi: 10.1016/j.joms.2007.06.649]

39.Hatano N, Sennerby L, Lundgren S. Maxillary sinus augmentation using sinus membrane elevation and peripheral venous blood for implant-supported rehabilitation of the atrophic posterior maxilla: case series. Clin Implant Dent Relat Res. 2007 Sep;9(3):150-5. [Medline: 17716259] [doi: 10.1111/j.1708- 8208.2007.00043.x]

40.Johansson LÅ, Isaksson S, Adolfsson E, Lindh C, Sennerby L. Bone regeneration using a hollow hydroxyapatite space-maintaining device for maxillary sinus floor augmentation--a clinical pilot study. Clin Implant Dent Relat Res. 2012 Aug;14(4):575-84. Epub 2010 Jun 2. [Medline: 20586781] [doi:10.1111/j.1708- 8208.2010.00293.x]

42.Kaneko T, Masuda I, Horie N, Shimoyama T. New bone formation in nongrafted sinus lifting with spacemaintaining management: a novel technique using a titanium bone fixation device. J Oral Maxillofac Surg. 2012 Mar;70(3):e217-24.[Medline: 22374065] [doi: 10.1016/j.joms.2011.10.025]

43.Tatum OH Jr. Maxillary and sins implant reconstructions. Dent Clin North Am 1986;30:207-229.

Boyne PJ, James RA. Grafting of the maxillary sinus floor with autogenous marrow and bone. J Oral Surg 1980;38:613–616.